

## Glossary of Osteopathic Terminology Usage Guide

The Glossary of Osteopathic Terminology is revised twice each year by the Educational Council on Osteopathic Principles, Chairman, John C. Glover, DO. Forward any comments or suggestions to John Glover, DO, FAAO, Chairman, Department of Osteopathic Manipulative Medicine, Touro University, California, 1310 Johnson Lane, Vallejo, CA 94592. Office Phone: (707) 638-5245, E-mail: jglover@touro.edu.

The Glossary first appeared in the *Journal of the American Osteopathic Association* (JAOA 80: 552-567) in April of 1981. The 1995 version of the Glossary of Osteopathic Terminology was also published in the textbook, *Foundations for Osteopathic Medicine*, Ward RC (ed.) (1997) pp. 1126-1140: Williams & Wilkins, Baltimore, MD, and in *Foundations for Osteopathic Medicine*, Ward RC (ed.) (2003) pp. 1229-1253: Williams & Wilkins, Baltimore, MD. The most current and revised version is available on the AACOM website at [www.aacom.org](http://www.aacom.org) in PDF format. It is also available on the AOA website at [www.osteopathic.org](http://www.osteopathic.org).

The April 2006 glossary review was performed by Andrea Clem, D.O., Lisa DeStefano, D.O., William Devine, D.O., Walter Ehrenfreuchter, D.O., FAAO, David Essig-Beatty, D.O., Heather Ferrell, D.O., Tom Fotopolis, D.O., Wolfgang Gilliar, D.O., John Glover, D.O., FAAO, Kurt Heinking, D.O., Jan Hendryx, D.O., Ray Hruby, D.O., FAAO, John Jones, D.O., Robert Kappler, D.O., FAAO, Sean Kerger, D.O., Randy Litman, D.O., Michael Lockwood, D.O., David Mason, D.O., Evan Nicholas, D.O., Kendi Pim, D.O., Paul Rennie, D.O., FAAO, Mark Sandhouse, D.O., Harriet Shaw, D.O., Greg Thompson, D.O., Kevin Treffer, D.O.

### Purpose:

The purpose of this osteopathic glossary is to present important and often used words, terms and phrases of the osteopathic profession. It is not meant to replace a dictionary. The glossary offers the consensus of a large segment of the osteopathic profession and serves to standardize terminology. The ECOP Glossary Review Committee specifically seeks to include those definitions that are uniquely osteopathic in their origin or common usage, distinctive in the osteopathic usage of a common word, and/or important in describing OPP/OMT. In the glossary, the term "osteopathic practitioner" refers to an osteopath, an osteopathic physician or an allopathic physician who has been trained in osteopathic principles, practices and philosophy. "Methods" are described as being direct, indirect or combined. "Osteopathic manipulative treatment systems" are complete systems of diagnosis and treatment such as high velocity low amplitude (HVLA), muscle energy and osteopathy in the cranial field. "Techniques" are those methods used within a treatment system such as lumbar rolls, rib-raising, etc.

This glossary should be useful to the student of osteopathic medicine and helpful to authors and other professionals in understanding and making proper use of osteopathic vocabulary.

The five models used in discussion of osteopathic patient care are the respiratory-circulatory model, the biomechanical-structural, metabolic-nutritional, neurological and behavioral-biopsychosocial. For a more complete description of the models and their application to patient care, please refer to the Educational Council on Osteopathic Principles Core Curriculum, copyright 1987, second edition copyright 2000. Electronic copies are available from the American Association of Colleges of Osteopathic Medicine.

Definitions are included from:

*Dorland's Medical Dictionary*, 29th edition, 2000  
The William & Wilkins Company, Baltimore, MD

*Stedman's Medical Dictionary*, 27th edition, 2000  
W.B. Saunders Company, Philadelphia, PA

*Foundations for Osteopathic Medicine*, 2nd edition, 2003  
Ward, Robert, ed.  
Lippincott Williams & Wilkins, Philadelphia, PA

*Rehabilitation Medicine, Principles and Practices*, 1st edition, 1988  
DeLisa, Joel A., ed.  
J.B. Lippincott, Philadelphia, PA

---

## Glossary of Osteopathic Terminology

Prepared by the Educational Council on Osteopathic Principles (ECOP) of the American Association of Colleges of Osteopathic Medicine (AACOM).

Revised July 2006.

©2006 The Educational Council on Osteopathic Principles and the American Association of Colleges of Osteopathic Medicine

---

### A

**abbreviations:** types of osteopathic manipulative treatment.

*ART:* articulatory treatment

*BLT:* balanced ligamentous tension treatment

*CR:* osteopathy in the cranial field

*CS:* counterstrain treatment

*D:* direct treatment

*DIR:* direct treatment

*FPR:* facilitated positional release treatment

*HVLA:* high velocity/low amplitude treatment

*I:* indirect treatment

*IND:* indirect treatment

*INR:* integrated neuromusculoskeletal release treatment

*LAS:* ligamentous articular strain treatment

*ME:* muscle energy treatment

*MFR:* myofascial release treatment

*NMM-OMM:* neuromusculoskeletal medicine

*OCF:* osteopathy in the cranial field/cranial treatment

*OMTh:* osteopathic manipulative therapy (non-US terminology)

*OMT:* osteopathic manipulative treatment

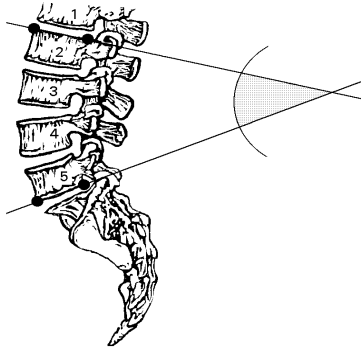
*PINS:* progressive inhibition of neuromuscular structures

*ST:* soft tissue treatment

*VIS:* visceral manipulative treatment

**accessory joint motions:** See *secondary joint motion*.

**accessory movements:** Movements used to potentiate, accentuate, or compensate for an impairment in a physiologic motion (e.g., the movements needed to move a paralyzed limb).



**Figure 1. Lumbolumbar angle (L2-L5).**

**accommodation:** A self-reversing and nonpersistent adaptation.

**active motion:** See *motion, active*.

**acute somatic dysfunction:** See *somatic dysfunction, acute*.

**allopathy:** 1. A therapeutic system in which a disease is treated by producing a second condition that is incompatible with or antagonistic to the first. (*Stedman's*)

**allopath:** A term used to refer those holding a Doctor of Medicine (MD) degree, a non-osteopathic medical degree.

**anatomical barrier:** See *barrier, (motion barrier)*.

**angle:**

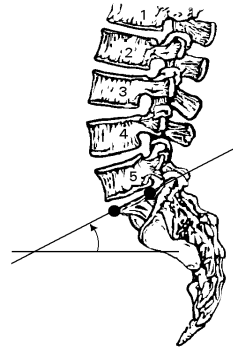
**Ferguson a.,** See *angle, lumbosacral*.

**lumbolumbar lordotic a.,** an objective quantification of lumbar lordosis typically determined by measuring the angle between the superior surface of the second lumbar vertebra and the inferior surface of the fifth lumbar vertebra; best measured from a standing lateral x-ray film. (**Fig. 1**)

**lumbosacral a.,** represents the angle of the lumbosacral junction as measured by the inclination of the superior surface of the first sacral vertebra to the horizontal (this is actually a sacral angle); usually measured from standing lateral x-ray films; also known as Ferguson's angle. (**Fig. 2**)

**lumbosacral lordotic a.,** an objective quantification of lumbar lordosis typically determined by measuring the angle between the superior surface of the second lumbar vertebra and the superior surface of the first sacral segment; best measured from a standing lateral x-ray film. (**Fig. 3**)

**anterior component:** A positional descriptor used to identify the side of reference when rotation of a vertebra has occurred; in a condition of right



**Figure 2. Lumbosacral angle (S1-horizon) (Ferguson's angle).**

rotation, the left side is the anterior component; usually refers to the less prominent transverse process; See also *posterior component*.

**anterior compression test:** See *ASIS (anterior superior iliac spine) compression test*.

**anterior iliac rotation:** See *ilium, somatic dysfunction of, anterior (forward) innominate (iliac) rotation*.

**anterior nutation,** See *nutation*.

**anterior rib:** See *rib somatic dysfunction, inhalation rib dysfunction*.

**ART:** See *TART*.

**articular pillar:** 1. Refers to the columnar arrangement of the articular portions of the cervical vertebrae. 2. Those parts of the lateral arches of the cervical vertebrae that contain a superior and inferior articular facet.

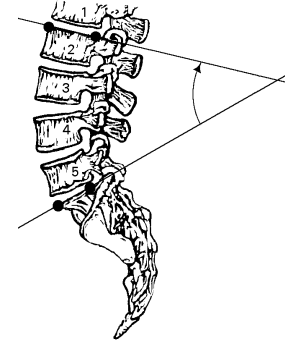
**articulation:** 1. The place of union or junction between two or more bones of the skeleton. 2. The active or passive process of moving a joint through its permitted anatomic range of motion. See also *osteopathic manipulative treatment, articular treatment (ART) system*.

**articular pop:** The sound made when cavitation occurs in a joint. See also *cavitation*.

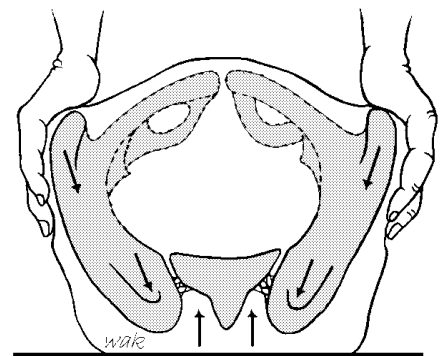
**articular technique:** See also *technique*. See *osteopathic manipulative treatment, articular treatment (ART) system*.

**asymmetry:** Absence of symmetry of position or motion; dissimilarity in corresponding parts or organs on opposite sides of the body that are normally alike; of particular use when describing position or motion alteration resulting from somatic dysfunction.

**axis:** 1. An imaginary line about which motion occurs. 2. The second cervical vertebra. 3. One component of an axis system.



**Figure 3. Lumbosacral lordotic angle.**



**Figure 4. ASIS compression test**

**axis of rib motion:** See *rib motion, axis*.

**ASIS (anterior superior iliac spine) compression test:** 1. A test for lateralization of somatic dysfunction of the sacrum, innominate or pubic symphysis. 2. Application of a force through the ASIS into one of the pelvic axes to assess the mechanics of the pelvis. See also *sacral motion, axis of (Fig. 4)*.

**axis of sacral motion:** See *sacral motion, axis of*.

**axoplasmic flow:** See *axoplasmic transport*.

**axoplasmic transport:** The antegrade movement of substances from the nerve cell along the axon toward the terminals, and the retrograde movement from the terminals toward the nerve cell.

## B

**backward bending:** Opposite of forward bending. See *extension*.

**backward bending test:** 1. This test discriminates between forward and backward sacral torsion/rotation. 2. This test discriminates between

unilateral sacral flexion and unilateral sacral extension.

**backward torsion:** See *sacrum, somatic dysfunctions of, backward torsions.*

**balanced ligamentous tension**

**technique:** See *osteopathic manipulative treatment, balanced ligamentous tension.* See also *osteopathic manipulative treatment, ligamentous articular strain.*

**barrier (motion barrier):** The limit to motion; in defining barriers, the palpatory end-feel characteristics are useful. (Fig. 5)

**anatomic b.,** the limit of motion imposed by anatomic structure; the limit of passive motion.

**elastic b.,** the range between the physiologic and anatomic barrier of motion in which passive ligamentous stretching occurs before tissue disruption.

**pathologic b.,** a restriction of joint motion associated with pathologic change of tissues (example: osteophytes). See also *barrier, restrictive b.*

**physiologic b.,** the limit of active motion.

**restrictive b.,** a functional limit that abnormally diminishes the normal physiologic range.

**batwing deformity:** See *transitional vertebrae, sacralization.*

**bind:** Palpable resistance to motion of an articulation or tissue. Synonym: resistance. Antonyms: ease, compliance, resilience.

**biomechanics:** Mechanical principles applied to the study of biological functions; the application of mechanical laws to living structures; the study and knowledge of biological function from an application of mechanical principles.

**body unity:** One of the basic tenets of the osteopathic philosophy; the human being is a dynamic unit of function; See also *osteopathic philosophy.*

**bogginess:** A tissue texture abnormality characterized principally by a palpable sense of sponginess in the tissue, interpreted as resulting from congestion due to increased fluid content.

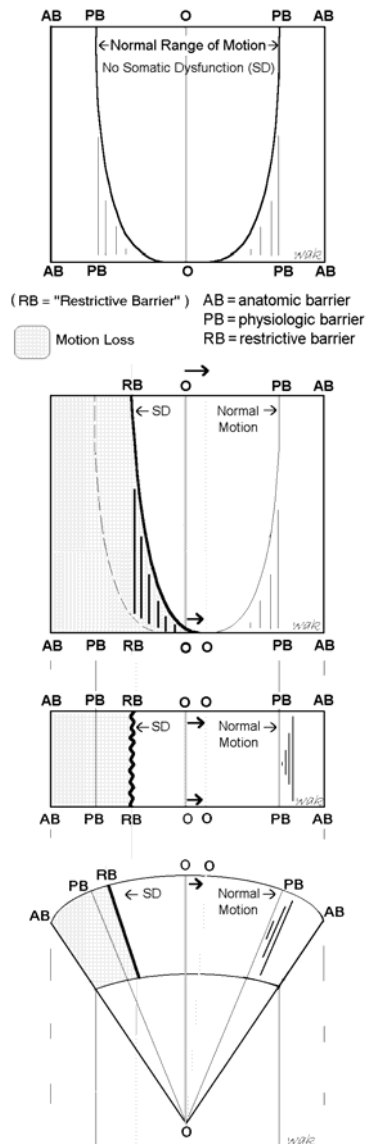
**bucket handle rib motion:** See *rib motion, bucket handle.*

## C

**caliper rib motion:** See *rib motion, caliper rib motion.*

**caudad:** Toward the tail or inferiorly.

### Concepts Regarding Joint Motion in a Single Plane



**Figure 5. Somatic dysfunction in a single plane: three methods illustrating the “restrictive barrier” (the restrainer): AB, anatomic barrier; PB, physiologic barrier; RB, restrictive barrier; SD, somatic dysfunction** (From *Foundations for Osteopathic Medicine*, Baltimore, William & Wilkins, 1997:484.

**caught in inhalation:** See *inhalation rib dysfunction.*

**caught in exhalation:** See *exhalation rib dysfunction.*

**cavitation:** The formation of small vapor and gas bubbles within fluid caused by local reduction in pressure. This phenomenon is believed to produce

an audible “pop” in certain forms of OMT.

**cephalad:** Toward the head.

**cephalad pubic dysfunction:** See *pubic bone, somatic dysfunctions of, superior pubic shear.*

**cerebrospinal fluid, fluctuation of:** A description of the hypothesized action of cerebrospinal fluid with regard to the craniosacral mechanism.

**cervicolumbar reflex:** See *reflex, cervicolumbar r.*

**Chapman reflex:** 1. A system of reflex points that present as predictable anterior and posterior fascial tissue texture abnormalities (plaque-like changes or stringiness of the involved tissues) assumed to be reflections of visceral dysfunction or pathology. 2. Originally used by Frank Chapman, DO, and described by Charles Owens, DO.

**chronic somatic dysfunction:** See *somatic dysfunction, chronic.*

**circumduction:** 1. The circular movement of a limb. 2. The rotary movement by which a structure is made to describe a cone, the apex of the cone being a fixed point (e.g., the circular movement of the shoulder).

**combined technique:** See *osteopathic manipulative treatment, combined method.*

**common compensatory pattern:** See *fascial patterns, common compensatory pattern.*

**compensatory fascial patterns:** See *fascial patterns, common compensatory pattern.*

**complete motor asymmetry:** Asymmetry of palpatory responses to all regional motion inputs including rotation, translation and active respiration.

**compliance:** 1. The ease with which a tissue may be deformed. 2. Direction of ease in motion testing.

**compression:** 1. Somatic dysfunction in which two structures are forced together. 2. A force that approximates two structures.

**conditioned reflex:** See *reflex, conditioned r.*

**contraction:** Shortening and/or development of tension in muscle.

**concentric c.,** contraction of muscle resulting in approximation of attachments.

**eccentric c.,** lengthening of muscle during contraction due to an external force.

**isokinetic c.,** 1. A concentric contraction against resistance in which the angular change of joint motion is at

the same rate. 2. The counterforce is less than the patient force.

**isolytic c.**, 1. A form of eccentric contraction designed to break adhesions using an operator-induced force to lengthen the muscle. 2. The counterforce is greater than the patient force.

**isometric c.**, 1. Change in the tension of a muscle without approximation of muscle origin and insertion. 2. Operator force equal to patient force.

**isotonic c.**, 1. A form of concentric contraction in which a constant force is applied. 2. Operator force less than patient force.

**contracted muscle:** The physiologic response to a neuromuscular excitation. See also *contractured muscle*.

**contracture:** A condition of fixed high resistance to passive stretch of a muscle, resulting from fibrosis of the tissues supporting the muscles or the joints, or from disorders of the muscle fibers.

**Dupuytren c.**, shortening, thickening and fibrosis of the palmar fascia, producing a flexion deformity of a finger (*Dorland's*).

**contractured muscle:** histological change substituting non-contractile tissue for muscle tissue, which prevents the muscle from reaching normal relaxed length. See also *contracted muscle*.

**core link:** The connection of the spinal dura mater from the occiput at the foramen magnum to the sacrum. It coordinates the synchronous motion of these two structures.

**coronal plane:** See *plane, frontal*.

**costal dysfunction:** See *rib, dysfunction*.

**counternutation:** Posterior movement of the sacral base around a transverse axis in relation to the ilia. See also *nutation*.

**counterstrain technique:** See *osteopathic manipulative treatment, counterstrain*.

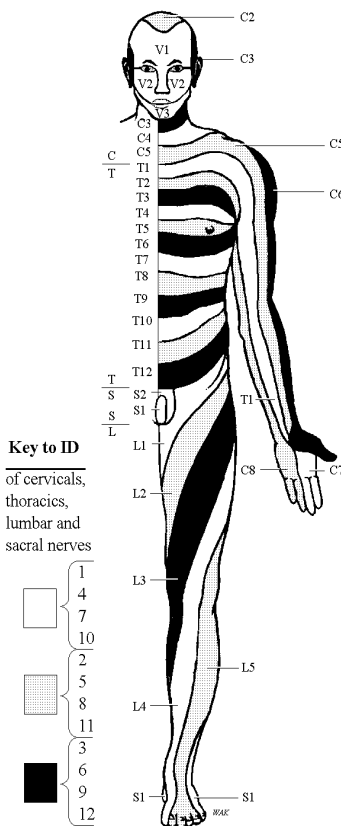
**cranial manipulation:** See *osteopathic manipulative treatment, cranial manipulation*.

**cranial rhythmic impulse (CRI):** 1. A palpable, rhythmic fluctuation believed to be synchronous with the primary respiratory mechanism. 2. Term coined by John Woods, DO, and Rachel Woods, DO.

**cranial technique:** See *osteopathic manipulative treatment, osteopathy in the cranial field*. See also *primary respiratory mechanism*.

**cranosacral manipulation:** See *osteopathic manipulative treatment, osteopathy in the cranial field*.

**cranosacral mechanism:** 1. A term used to refer to the anatomical connection



**Figure 6. Dermatomal map (anterior).** (Modified from Agur AMR, *Grant's Atlas of Anatomy*, 9<sup>th</sup> ed. Baltimore Md: Williams & Wilkins; 1991:37).

between the occiput and the sacrum by the spinal dura mater. 2. A term coined by William G. Sutherland, DO. See also *extension, cranosacral extension and flexion, cranosacral flexion*.

**C-SPOMM:** Certification Special Proficiency in Osteopathic Manipulative Medicine. Granted by the American Osteopathic Association through the American Osteopathic Board of Special Proficiency in Osteopathic Manipulative Medicine from 1989 through 1999. See also *NMM-OMM*.

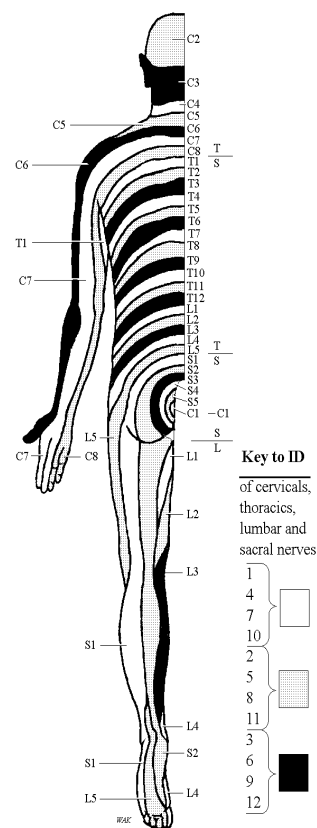
**creep:** The capacity of fascia and other tissue to lengthen when subjected to a constant tension load resulting in less resistance to a second load application.

**CV-4:** See *osteopathic manipulative treatment, CV-4*.

## D

**Dalrymple treatment:** See *osteopathic manipulative treatment, pedal pump*.

**decompensation:** A dysfunctional, persistent pattern, in some cases



**Figure 7. Dermatomal map (posterior).** (Modified from Agur AMR, *Grant's Atlas of Anatomy*, 9<sup>th</sup> ed. Baltimore Md: Williams & Wilkins; 1991:37).

reversible, resulting when homeostatic mechanisms are partially or totally overwhelmed

**depressed rib:** See *rib somatic dysfunction, exhalation rib dysfunction*.

**dermatome:** 1. The area of skin supplied by cutaneous branches from a single spinal nerve. (Neighboring dermatomes may overlap.) 2. Cutis plate; the dorsolateral part of an embryonic somite. (**Fig. 6 and Fig. 7**)

**diagnostic palpation:** See *palpatory diagnosis*.

**diagonal axis:** See *sacral, oblique axis, diagonal*.

**direct method (technique):** See *osteopathic manipulative treatment, direct treatment*.

**DO:** 1. Doctor of Osteopathy (accredited by the American Osteopathic Association). 2. Doctor of Osteopathic Medicine (accredited by the American Osteopathic Association). 3. Diplomate in Osteopathy (The first degree granted by American School of Osteopathy). 4. Diplomate of Osteopathy, a degree granted by some schools of osteopathy outside the United States.

**drag:** See *skin drag*.

## E

**ease:** Relative palpable freedom of motion of an articulation or tissue. Synonyms: compliance, resilience. Antonyms: bind, resistance.

**easy normal:** See *neutral, definition number 2*.

**-ed:** A suffix describing status, position, or condition (e.g., extended, flexed, rotated, restricted).

**effleurage:** Stroking movement used to move fluids.

**elastic deformation:** Any recoverable deformation. See also *plastic deformation*.

**elasticity:** Ability of a strained body or tissue to recover its original shape after deformation. See also *plasticity and viscosity*.

**elevated rib:** See *rib somatic dysfunction, inhalation rib dysfunction*. See also *rib motion, exhalation rib restriction*.

**end feel:** Perceived quality of motion as an anatomic or physiologic restrictive barrier is approached.

**enthesitis:** 1. Traumatic disease occurring at the insertion of muscles where recurring concentration of muscle stress provokes inflammation with a strong tendency toward fibrosis and calcification (*Stedman's*). 2. Inflammation of the muscular or tendinous attachment to bone (*Dorland's*).

**ERS:** A descriptor of spinal somatic dysfunction used to denote a combination extended (E), rotated (R), and sidebent (S) vertebral position.

**ERS left,** somatic dysfunction in which the vertebral unit is extended, rotated and sidebent left; usually preceded by a designation of the vertebral unit(s) involved (e.g., T5 ERS left or T5 ER<sub>L</sub>S<sub>L</sub>).

**ERS right,** somatic dysfunction in which the vertebral unit is extended, rotated and sidebent right; usually preceded by a designation of the vertebral unit(s) involved (e.g., C3-5 ERS right or C3-5 ER<sub>R</sub>S<sub>R</sub>).

**exaggeration method:** See *osteopathic manipulative treatment, exaggeration method*.

**exaggeration technique:** See *osteopathic manipulative treatment, exaggeration technique*.

**exhaled rib:** (Archaic) using positional (static) diagnosis. See *rib somatic dysfunction, exhalation rib dysfunction*.

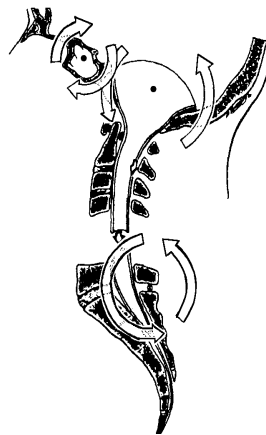
**exhalation rib dysfunction:** See *rib somatic dysfunction, exhalation rib dysfunction*.

**exhalation rib restriction:** See *rib motion, exhalation rib restriction*. See also *rib somatic dysfunction, inhalation rib dysfunction*.

**exhalation strain:** See *rib somatic dysfunction, exhalation rib dysfunction*.

**extension:** 1. Accepted universal term for backward motion of the spine in a sagittal plane about a transverse axis; in a vertebral unit when the superior part moves backward. 2. In extremities, it is the straightening of a curve or angle (biomechanics). 3. Separation of the ends of a curve in a spinal region; See *extension, regional extension*.

**craniosacral extension,** motion occurring during the cranial rhythmic impulse when the sphenobasilar symphysis descends and sacral base moves anteriorly. (**Fig. 8**)



**Figure 8. Craniosacral extension.**

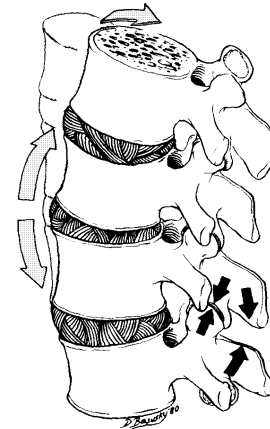
**regional extension,** historically, the straightening in the sagittal plane of a spinal region; also called Fryette's regional extension. (**Fig. 9**)

**sacral extension,** posterior movement of the base of the sacrum in relation to the ilia. (**Fig. 10**) See also *flexion, sacral flexion*.

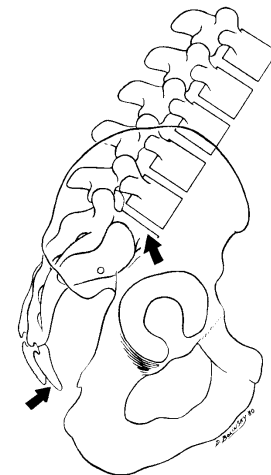
**extrinsic corrective forces:** Treatment forces external to the patient that may include operator effort, effect of gravity, mechanical tables, etc. See also *intrinsic corrective forces*.

## F

**FAAO:** 1. Fellow of American Academy of Osteopathy. 2. This fellowship is an earned post-doctoral degree conferred by the American Academy of Osteopathy. Those who earn the FAAO degree must have demonstrated



**Figure 9. Regional extension.**



**Figure 10. Sacral extension.**

their commitment to osteopathic principles and practice through teaching, writing, and professional service, performed at the highest level of professional and ethical standards.

**facet asymmetry:** Configuration in which the structure, position and/or motion of the facets are not equal bilaterally. See also *facet symmetry and tropism, facet*.

**facet symmetry:** Configuration in which the structure, position and/or motion of the facets are equal bilaterally. See also *facet asymmetry and symmetry*.

**facilitated positional release:** See *osteopathic manipulative treatment, facilitated positional release*.

**facilitated segment:** See *spinal facilitation*.

**facilitation:** See *spinal facilitation*.

**fascial patterns:** 1. Systems for classifying and recording the preferred directions of fascial motion throughout the body. 2. Based on the observations

of J. Gordon Zink, DO, and W. Neidner, DO.

**common compensatory pattern (CCP)**, the specific finding of alternating fascial motion preference at transitional regions of the body described by Zink and Neidner. (Fig. 11)

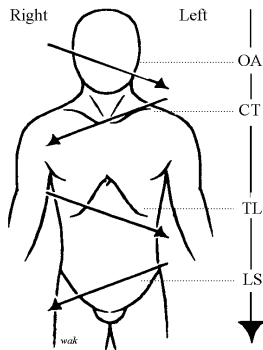


Figure 11. Common compensatory fascial pattern (Zink)

**uncommon compensatory pattern**, the finding of alternating fascial motion preference in the direction opposite that of the common compensatory pattern described by Zink and Neidner. (Fig. 12)

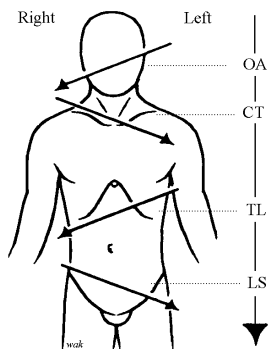


Figure 12. Uncommon compensatory fascial pattern (Zink).

**uncompensated fascial pattern**, the finding of fascial preferences that do not demonstrate alternating patterns of findings at transitional regions. Because they occur following stress or trauma, they tend to be symptomatic.

**fascial release technique:** See *osteopathic manipulative treatment, myofascial release*.

**fascial unwinding:** See *osteopathic manipulative treatment, fascial unwinding*.

**Ferguson angle:** See *angle, lumbosacral*.

**flexion:** 1. Accepted universal term for forward motion of the spine, in its

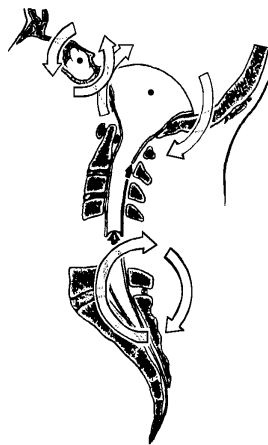


Figure 13. Craniosacral flexion.

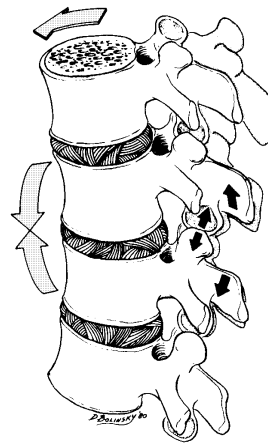


Figure 14. Regional flexion.

sagittal plane about a transverse axis, where the superior part moves forward.

2. In the extremities, it is the approximation of a curve or angle (biomechanics). 3. Approximation of the ends of a curve in a spinal region; also called Fryette's regional flexion. See *flexion, regional flexion*.

**craniosacral flexion**, motion occurring during the cranial rhythmic impulse, when the sphenobasilar symphysis ascends and the sacral base moves posteriorly. (Fig. 13)

**regional flexion**, historically, is the approximation of the ends of a curve in the sagittal plane of the spine; also called Fryette's regional flexion. (See *flexion* (Fig. 14).

**sacral flexion**, anterior movement of sacral base in relation to the ilia. (Fig. 15) See also *extension, sacral extension*.

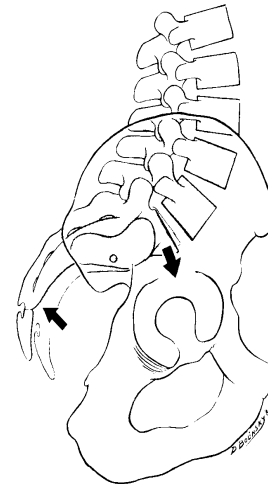


Figure 15. Sacral flexion.

**flexion left:** See *sidebending*.

**flexion right:** See *sidebending*.

**flexion tests:** Tests for iliosacral or sacroiliac somatic dysfunction.

**seated flexion test**, a screening test that determines the side of sacroiliac somatic dysfunction (motion of the sacrum on the ilium).

**standing flexion test**, a screening test that determines the side of iliosacral somatic dysfunction (motion of ilium on the sacrum).

**forward bending.** Reciprocal of backward bending. See *flexion*.

**forward torsions:** See *sacrum, somatic dysfunctions of, forward torsions*.

**FRS:** A descriptor of spinal somatic dysfunction used to denote a combination flexed (F), rotated (R), and sidebent (S) vertebral position.

**FRS left**, somatic dysfunction in which the vertebral unit is flexed, rotated and sidebent left; usually preceded by a designation of the vertebral unit(s) involved (e.g., T5 FRS left or T5 FRLSL).

**FRS right**, somatic dysfunction in which the vertebral unit is flexed, rotated and sidebent right; usually preceded by a designation of the vertebral unit(s) involved (e.g., C3-5 FRS right or C3-5 FRRSR).

**frontal plane:** See *plane, frontal*.

**Fryette laws:** See *laws, Fryette's*. See *physiologic motion of the spine*.

**Fryette principles:** See *physiologic motion of the spine*.

**Fryette regional extension:** See *extension, regional extension*.

**Fryette regional flexion:** See *flexion, regional flexion*.

**FSR:** A descriptor of spinal somatic dysfunction used to denote a combination flexed (F), sidebent (S), and rotated (R) vertebral position. See *FRS*.

**functional method:** See *osteopathic manipulative treatment, functional method*.

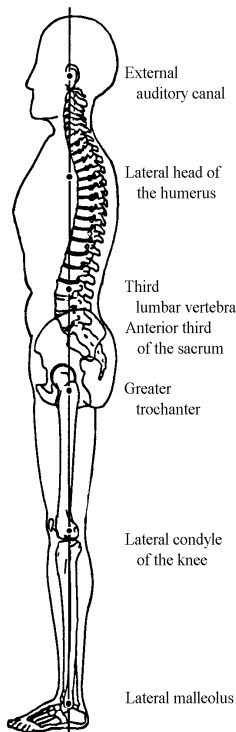
**functional technique:** See *osteopathic manipulative treatment, functional method*.

## G

**gait:** a forward translation of the body's center of gravity by bipedal locomotion. (*DeLisa*)

**Galbreath treatment:** See *osteopathic manipulative treatment, mandibular drainage*.

**gravitational line:** Viewing the patient from the side, an imaginary line in a coronal plane which, in the theoretical ideal posture, starts slightly anterior to the lateral malleolus, passes across the lateral condyle of the knee, the greater trochanter, through the lateral head of the humerus at the tip of the shoulder to the external auditory meatus; if this were a plane through the body, it would intersect the middle of the third lumbar vertebra and the anterior one third of the sacrum. It is used to evaluate the A-P (anterior-posterior) curves of the spine. See also *mid-malleolar line*. (**Fig. 16**)



**Figure 16. Gravitational**

**guiding:** Gentle movement by the operator following the path of least resistance in the movement of a body part within its normal range.

## H

**habituation:** Decreased physiologic response to repeated stimulation.

**hatchet head:** See *scaphocephaly*.

**health:** Adaptive and optimal attainment of physical, mental, emotional, spiritual and environmental well-being.

**hepatic pump:** See *osteopathic manipulative treatment, hepatic pump*.

**high velocity/low amplitude technique (HVLA):** See *osteopathic manipulative treatment, high velocity/low amplitude technique (HVLA)*.

**hip bone:** See *innominate*. See also *innominate, somatic dysfunctions of*.

**homeostasis:** 1. Maintenance of static or constant conditions in the internal environment. 2. The level of well-being of an individual maintained by internal physiologic harmony that is the result of a relatively stable state or equilibrium among the interdependent body functions.

**homeostatic mechanism:** A system of control activated by negative feedback (*Dorland's*).

**Hoover technique:** See *osteopathic manipulative treatment, Hoover technique*.

**hysteresis:** During the loading and unloading of connective tissue, the restoration of the final length of the tissue occurs at a rate and to an extent *less than* during deformation (*loading*). These differences represent energy loss in the connective tissue system. This difference in viscoelastic behavior (*and energy loss*) is known as hysteresis (or "stress-strain"). (*Foundations, Second Edition, page 1158*).

**hypertonicity:** 1. A condition of excessive tone of the skeletal muscles. 2. Increased resistance of muscle to passive stretching.

## I

**ILA:** See *sacrum, inferior lateral angle of*.

**ilia:** The plural of ilium. See *ilium*.

**ilial compression test:** See *ASIS compression test*.

**ilial rocking test:** See *ASIS compression test*.

**iliosacral motion:** Motion of one innominate (ilium) with respect to the sacrum. Iliosacral motion is part of pelvic motion during the gait cycle.

**ilium:** the expansive superior portion of the innominate (hip bone or os coxae).

**indirect method:** See *osteopathic manipulative treatment, indirect method*.

**inferior ilium:** See *innominate, somatic dysfunctions of, inferior innominate shear*.

**inferior lateral angle (ILA) of the sacrum:** See *sacrum, inferior lateral angle*.

**inferior pubis:** See *pubic bone, somatic dysfunctions of, inferior pubic shear*.

**inferior transverse axis:** See *sacral motion axis, inferior transverse axis*.

**inhalation rib:** See *rib somatic dysfunction, inhalation rib dysfunction*.

**inhalation rib restriction:** See *rib somatic dysfunction, inhalation rib dysfunction*.

**inhalation strain:** See *rib somatic dysfunction, inhalation rib dysfunction*.

**inhibition reflex:** 1. In osteopathic usage, a term that describes the application of steady pressure to soft tissues to effect relaxation and normalize reflex activity. 2. Effect on antagonist muscles due to reciprocal inhibition when the agonist is stimulated. See also *law, Sherrington's*. See also *osteopathic manipulative treatment, inhibitory pressure technique*.

**inhibitory pressure technique:** See *osteopathic manipulative treatment, inhibitory pressure technique*.

**innominate:** The os coxae is a large irregular shaped bone that consists of three parts: ilium, ischium and pubis, which meet at the acetabulum, the cup shaped cavity for the head of the femur at the hip (femoroacetabular) joint. Also called the innominate bone or pelvic bone. See also *hip bone*.

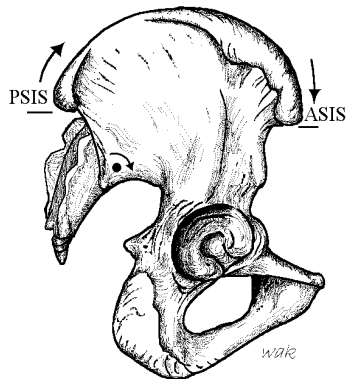
**innominate rotation:** Rotational motion of one innominate bone relative to the sacrum on the inferior transverse axis.

**innominate, somatic dysfunctions of:**

**anterior innominate rotation,** a somatic dysfunction in which the anterior superior iliac spine (ASIS) is anterior and inferior to the contralateral landmark. The innominate (os coxae) moves more freely in an anterior and inferior direction, and is restricted from movement in a posterior and superior direction. (**Fig. 17**)

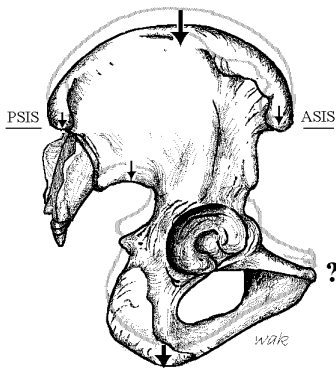
**downslipped innominate,** See *inferior innominate shear*.

**inferior innominate shear,** a somatic dysfunction in which the anterior superior iliac spine (ASIS) and posterior superior iliac spines (PSIS) are inferior to the contralateral landmarks. The innominate (os coxae)



Seated flexion test = R(+)

**Figure 17. Anterior right innominate. Forced anterior rotation can also result in an inferior pubic shear.**



Seated flexion test = R(+)

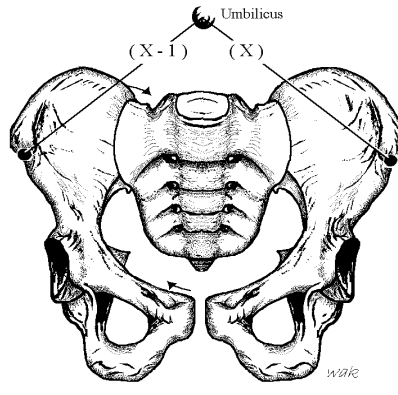
**Figure 18. Right inferior innominate shear. This also may or may not result in an inferior pubic shear.**

moves more freely in an inferior direction, and is restricted from movement in a superior direction. (Fig. 18)

**inflared innominate**, a somatic dysfunction of the innominate (os coxae) resulting in medial positioning of the anterior superior iliac spine (ASIS). The innominate moves more freely in a medial direction, and is restricted from movement in a lateral direction. (Fig. 19)

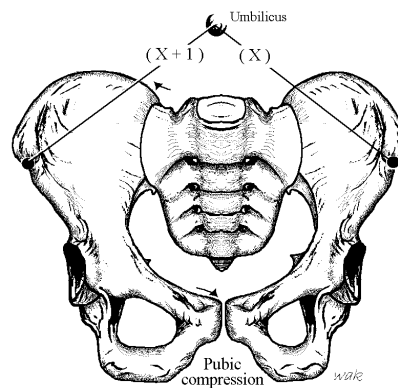
**outflared innominate**, a somatic dysfunction of the innominate (os coxae) resulting in lateral positioning of the anterior superior iliac spine (ASIS). The innominate moves more freely in a lateral direction, and is restricted from movement in a medial direction. (Fig. 20)

**posterior innominate rotation**, a somatic dysfunction in which the anterior superior iliac spine (ASIS) is posterior and superior to the contralateral landmarks. The



Seated flexion test = R(+)

**Figure 19. Inflared right innominate.**



Seated flexion test = R(+)

**Figure 20. Outflare right innominate.**

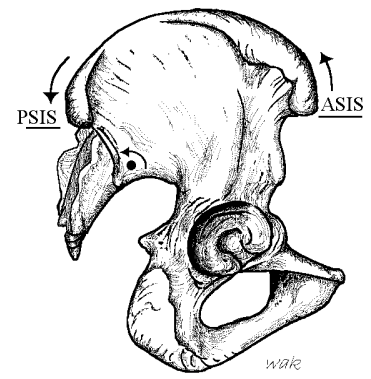
innominate (os coxae) moves more freely in a posterior and superior direction, and is restricted from movement in an anterior and inferior direction. (Fig. 21)

**superior innominate shear**, a somatic dysfunction in which the anterior superior iliac spine (ASIS) and posterior superior iliac spines (PSIS) are superior to the contralateral landmarks. The innominate (os coxa) moves more freely in a superior direction, and is restricted from movement in an inferior direction. (Fig. 22)

**upslipped innominate**, See *superior innominate shear*.

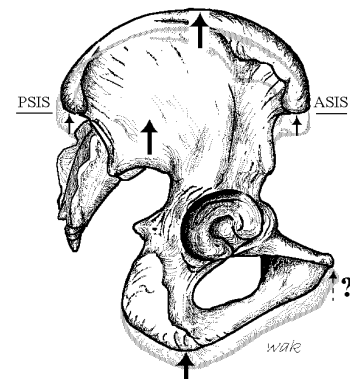
**integrated neuromusculoskeletal release**: See *osteopathic manipulative treatment, integrated neuromusculoskeletal release*.

**intersegmental motion**: Designates relative motion taking place between two adjacent vertebral segments or within a vertebral unit that is described as the upper vertebral segment moving on the lower.



Seated flexion test = R(+)

**Figure 21. Right posterior innominate. Forced posterior rotation may or may not result in a superior pubic shear.**



Seated flexion test = R(+)

**Figure 22. Right superior innominate shear. This also may or may not result in a superior pubic shear.**

**intrinsic corrective forces**: Voluntary or involuntary forces from within the patient that assist in the manipulative treatment process. See also *extrinsic corrective forces*.

**-ion**: A suffix describing a process or movement (e.g., extension, flexion, rotation, restriction).

**isokinetic exercise**: Exercise using a constant speed of movement of the body part.

**isolytic contraction**: See *contraction, isolytic c.*

**isometric contraction**: See *contraction, isometric c.*

**isotonic contraction**: See *contraction, isotonic c.*

## J

**Jones technique**: See *osteopathic manipulative treatment, counterstrain*.



**junctional region:** See *transitional region*.

## K

**key lesion:** The somatic dysfunction that maintains a total dysfunction pattern including other secondary dysfunctions.

**kinesthesia:** The sense by which muscular motion, weight, position, etc., are perceived.

**kinesthetic:** Pertaining to kinesthesia.

**kinetics:** The body of knowledge that deals with the effects of forces that produce or modify body motion.

**klapping:** Striking the skin with cupped palms to produce vibrations with the intention of loosening material in the lumen of hollow tubes or sacs within the body, particularly the lungs.

**kneading:** A soft tissue technique that utilizes an intermittent force applied perpendicular to the long axis of the muscle.

**kyphoscoliosis:** A spinal curve pattern combining kyphosis and scoliosis. See also *kyphosis*. See also *scoliosis*.

**kyphosis:** 1. The exaggerated (pathologic) A-P curve of the thoracic spine with concavity anteriorly. 2. Abnormally increased convexity in the curvature of the thoracic spine as viewed from the side (*Dorland's*).

**kyphotic:** Pertaining to or characterized by kyphosis.

## L

**lateral flexed vertebral body:** See *sidebent*.

**lateral flexion:** Also called lateroflexion. See *sidebending*.

**lateral masses (of the atlas):** The most bulky and solid parts of the atlas that support the weight of the head.

**lateroflexion:** See *sidebending*.

### law:

**Fryette I.** of motion, See *physiologic motion of the spine*.

**Head I.**, when a painful stimulus is applied to a body part of low sensitivity (e.g., viscus) that is in close central connection with a point of higher sensitivity (e.g., soma), the pain is felt at the point of higher sensitivity rather than at the point where the stimulus was applied.

**Lovett I.**, States that there is an association between the superior and inferior vertebrae, which are paired two by two. The cervical and superior thoracic biomechanics act in a synchronous manner with the lumbar

and inferior thoracic biomechanics. For example, if C1 is in a right posterior positional lesion, L5 also moves into a right posterior position. In this case, L5 is the "Lovett partner" of C1. The treatment of L5 helps to stabilize C1 and the skull by changing the lines of gravity. (French usage).

**Sherrington I.**, 1. Every posterior spinal nerve root supplies a specific region of the skin, although fibers from adjacent spinal segments may invade such a region. 2. When a muscle receives a nerve impulse to contract, its antagonist receives, simultaneously, an impulse to relax. (These are only two of Sherrington's contributions to neurophysiology; these are the ones most relevant to osteopathic principles.)

**Wolff I.**, every change in form and function of a bone, or in its function alone, is followed by certain definite changes in its internal architecture, and secondary alterations in its external conformations (*Stedman's, 25th ed.*); (e.g., bone is laid down along lines of stress).

**lesioned components:** See *osteopathic lesion*. See *somatic dysfunction*.

**lesion (osteopathic):** See *osteopathic lesion*.

### ligamentous:

**I. articular strain**, any somatic dysfunction resulting in abnormal ligamentous tension or strain. See also *osteopathic manipulative treatment, ligamentous articular strain technique*.

**I. articular strain technique**, See *osteopathic manipulative treatment, ligamentous articular strain technique*.

**I. strain**, motion and/or positional asymmetry associated with elastic deformation of connective tissue (fascia, ligament, membrane). See *strain and ligamentous articular strain*.

**line of gravity:** See *gravitational line*.

**linkage:** See *somatic dysfunction, linkage*.

**liver pump:** See *osteopathic manipulative treatment, hepatic pump*.

**localization:** 1. In manipulative technique, the precise positioning of the patient and vector application of forces required to produce a desired result. 2. The reference of a sensation to a particular locality in the body.

**longitudinal axis:** See *sacral, sacral motion axis, longitudinal axis*.

**lordosis:** 1. The anterior convexity in the curvature of the lumbar and cervical spine as viewed from the side. The term is used to refer to abnormally increased curvature (hollow back, saddle back, sway back) and to the

normal curvature (normal lordosis). (*Dorland's*). 2. Hollow back or saddle back; an abnormal extension deformity; anteroposterior curvature of the spine, generally lumbar with the convexity looking anteriorly (*Stedman's*).

**lordotic:** Pertaining to or characterized by lordosis.

**lumbarization:** See *transitional vertebrae, lumbarization*.

**lumbolumbar lordotic angle:** See *angle, lumbolumbar lordotic*.

**lumbosacral angle:** See *angle, lumbosacral*.

**lumbosacral lordotic angle:** See *angle, lumbosacral lordotic*.

**lumbosacral spring test:** See *spring test*.

**lymphatic pumps:** See *osteopathic manipulative treatment, lymphatic pump*. See also *osteopathic manipulative treatment, pedal pump*. See also *osteopathic manipulative treatment, thoracic pump*.

**lymphatic treatment:** Techniques used to optimize function of the lymphatic system. See *osteopathic manipulative treatment, lymphatic pump*. See also *osteopathic manipulative treatment, pedal pump*. See also *osteopathic manipulative treatment, thoracic pump*.

## M

**mandibular drainage technique:** See *osteopathic manipulative treatment, mandibular drainage technique*.

**manipulation:** Therapeutic application of manual force. See also *technique*. See also *osteopathic manipulative treatment*.

**manual medicine:** The skillful use of the hands to diagnose and treat structural and functional abnormalities in various tissues and organs throughout the body, including bones, joints, muscles and other soft tissues as an integral part of complete medical care. 1. This term originated from the German *Manuelle Medizin* (manual medicine) and has been used interchangeably with the term manipulation. 2. This term is not identical to manual therapy, which has been used by non-physician practitioners (e.g. physical therapists).

**massage:** Therapeutic friction, stroking, and kneading of the body. See also *osteopathic manipulative treatment, soft tissue treatment*.

**mechanoreceptor:** A receptor excited by mechanical pressures or distortions, such as those responding to touch and muscular contractions. (*Dorland's*).

**membranous articular strain:** Any cranial somatic dysfunction resulting in abnormal dural membrane tensions.

**membranous balance:** The ideal physiologic state of harmonious equilibrium in the tension of the dura mater of the brain and spinal cord.

**mesenteric lift:** See *osteopathic manipulative treatment, mesenteric release technique*.

**mesenteric release technique:** See *osteopathic manipulative treatment, mesenteric release technique*.

**middle transverse axis:** See *sacral motion axis, middle transverse axis (postural)*.

**mid-heel line:** A vertical line used as a reference in standing anteroposterior (A-P) x-rays and postural evaluation, passing equidistant between the heels.

**mid-gravitational line:** See *gravitational line*.

**mid-malleolar line:** A vertical line passing through the lateral malleolus, used as a point of reference in standing lateral x-rays and postural evaluation. See also *gravitational line*.

**mirror-image motion asymmetries:** A grouping of primary and secondary sites of somatic dysfunction describing a three-segment complex fundamental to dysfunction in a mobile system. Each adjacent segment, above and below the primary locus, demonstrates opposing asymmetries to that locus. For example, if the primary locus resists rotation right, the segments above and below resist rotation left.

**mobile point:** In counterstrain, the final position of treatment at which tenderness is no longer elicited by palpation of the tender point.

**mobile segment:** A term in functional methods to describe a bony structure with its articular surfaces and adnexal tissues (neuromuscular and connective) for segmental motion which affects movement, stabilizes position and allows coordinated participation in passive movement.

**mobile system:** An osteopathic construct associated with functional methods in which the body as a whole is viewed as a centrally integrated system in which all of the individual elements (e.g. mobile segments) have coordinated and specific motion characteristics. See also *functional methods*.

**mobile unit:** See *mobile segment*.

**models of osteopathic care:** Five models that articulate how an osteopathic practitioner seeks to influence a patient's physiological processes.

**structural model,** the goal of the structural model is biomechanical

adjustment and the mobilization of joints. This model also seeks to address problems in the myofascial connective tissues, as well as in the bony and soft tissues to remove restrictive forces and enhance motion. This is accomplished by the use of a wide range of osteopathic manipulative techniques such as high velocity-low amplitude, muscle energy, counterstrain, myofascial release, ligamentous articular techniques and functional techniques.

**respiratory-circulatory model,** the goal of the respiratory-circulatory model is to improve all of the diaphragm restrictions in the body. Diaphragms are considered to be "transverse restrictors" of motion, venous and lymphatic drainage and cerebrospinal fluid. The techniques used in this model are osteopathy in the cranial field, ligamentous articular strain, myofascial release and lymphatic pump techniques.

**metabolic model,** the goal of the metabolic model is to enhance the self-regulatory and self-healing mechanisms, to foster energy conservation by balancing the body's energy expenditure and exchange, and to enhance immune system function, endocrine function and organ function. The osteopathic considerations in this area are not manipulative in nature except for the use of lymphatic pump techniques. Nutritional counseling, diet and exercise advice are the most common approaches to balancing the body through this model.

**neurologic model,** the goal of the neurologic model is to attain autonomic balance and address neural reflex activity, remove facilitated segments, decrease afferent nerve signals and relieve pain. The osteopathic manipulative techniques used to influence this area of patient health include counterstrain and Chapman reflex points.

**behavioral model,** the goal of this model is to improve the biological, psychological and social components of the health spectrum. This includes emotional balancing and compensatory mechanisms. Reproductive processes and behavioral adaptation are also included under this model.

**motion:** 1. A change of position (rotation, and/or translation) with respect to a fixed system; 2. An act or process of a body changing position in terms of direction, course and velocity.

**active m.,** movement produced voluntarily by the patient.

**inherent m.,** spontaneous motion of every cell, organ, system and their component units within the body.

**m. barrier,** See *barrier (motion barrier)*.

**passive m.,** motion induced by the osteopathic practitioner while the patient remains passive or relaxed.

**physiologic m.,** changes in position of body structures within the normal range. See also *physiologic motion of the spine*.

**translatory m.,** motion of a body part along an axis. See also *translation*.

**muscle energy technique:** See *osteopathic manipulative treatment, muscle energy*.

**myofascial release technique:** See *osteopathic manipulative treatment, myofascial release*.

**myofascial technique:** See *osteopathic manipulative treatment, myofascial technique*.

**myofascial trigger point:** See *trigger point*.

**myogenic tonus:** 1. Tonic contraction of muscle dependent on some property of the muscle itself or of its intrinsic nerve cells. 2. Contraction of a muscle caused by intrinsic properties of the muscle or by its intrinsic innervation (*Stedman's*).

**myotome:** 1. All muscles derived from one somite and innervated by one segmental spinal nerve. 2. That part of the somite that develops into skeletal muscle (*Stedman's*).

## N

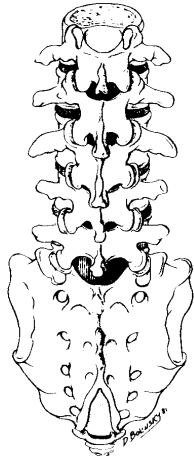
**neurotrophicity:** See *neurotrophy*.

**neurotrophy:** The nutrition and maintenance of tissues as regulated by direct innervation.

**neutral:** 1. The range of sagittal plane spinal positioning in which the first principle of physiologic motion of the spine applies. See also *physiologic motion of the spine*. 2. The point of balance of an articular surface from which all the motions physiologic to that articulation may take place. (**Fig. 23**)

**NMM-OMM:** Osteopathic neuromusculoskeletal medicine certification is granted by the American Osteopathic Association through the American Osteopathic Board of Neuromusculoskeletal Medicine. First granted in 1999.

**non-neutral:** The range of sagittal plane spinal positioning in which the second principle of physiologic motion of the



**Figure 23. Neutral spinal position.**

spine applies. See also *extension*. See also *flexion*. See also *physiologic motion of the spine*.

**normalization:** The therapeutic use of anatomic and physiologic mechanisms to facilitate the body's response toward homeostasis and improved health.

**NSR:** A descriptor of spinal somatic dysfunction used to denote a combination neutral (N), sidebent (S), and rotated (R) vertebral position; similar descriptors may involve flexed (F) and extended (E) position.

**nutation:** Nodding forward; anterior movement of the sacral base around a transverse axis in relation to the ilia.

## O

**oblique axis:** See *sacral motion axis, oblique (diagonal)*.

**OMM:** See *osteopathic manipulative medicine*.

**OMTh:** See *osteopathic manipulative therapy*.

**OMT:** See *osteopathic manipulative treatment*.

**ONM:** See *NMM-OMM*.

**OP&P:** Osteopathic principles and practice. See also *osteopathic philosophy*.

**os coxae:** See *innominate*.

**-osis:** word element [GR], disease; morbid state; abnormal increase.

**osteopath: 1.** A person who has achieved the nationally recognized academic and professional standards within her or his country to independently practice diagnosis and treatment based upon the principles of osteopathic philosophy. Individual countries establish the national academic and professional

standards for osteopaths practicing within their countries (International usage). 2. Considered by the American Osteopathic Association to be an archaic term when applied to graduates of U.S. schools.

**osteopathic lesion (osteopathic lesion complex):** Archaic term used to describe somatic dysfunction. See *somatic dysfunction*.

**Osteopathic Manipulative Medicine (OMM):** The application of osteopathic philosophy, structural diagnosis and use of OMT in the diagnosis and management of the patient.

**Osteopathic Manipulative Therapy (OMTh):** the therapeutic application of manually guided forces by an osteopath (non-physician) to improve physiological function and homeostasis that has been altered by somatic dysfunction.

**Osteopathic Manipulative Treatment (OMT):** The therapeutic application of manually guided forces by an osteopathic physician (US Usage) to improve physiologic function and/or support homeostasis that has been altered by somatic dysfunction. OMT employs a variety of techniques including:

**active method,** technique in which the person voluntarily performs an osteopathic practitioner-directed motion.

**articular treatment,** (archaic). See *osteopathic manipulative treatment, articular treatment system*.

**articular treatment system (ART),** a low velocity/moderate to high amplitude technique where a joint is carried through its full motion with the therapeutic goal of increased range of movement. The activating force is either a repetitive springing motion or repetitive concentric movement of the joint through the restrictive barrier.

**balanced ligamentous tension (BLT),** 1. According to Sutherland's model, all the joints in the body are balanced ligamentous articular mechanisms. The ligaments provide proprioceptive information that guides the muscle response for positioning the joint and the ligaments themselves guide the motion of the articular components. (Foundations) 2. First described in "Osteopathic Technique of William G. Sutherland", that was published in the *1949 Year Book of Academy of Applied Osteopathy*. See also *ligamentous articular strain*.

**Chapman reflex,** See *Chapman reflex*.  
**combined method,** 1. A treatment strategy where the initial movements are indirect; as the technique is

completed the movements change to direct forces. 2. A manipulative sequence involving two or more different osteopathic manipulative treatment systems (e.g., Spencer technique combined with muscle energy technique). 3. A concept described by Paul Kimberly, DO.

**combined treatment,** (archaic). See *osteopathic manipulative treatment, combined method*.

**compression of the fourth ventricle (CV-4),** a cranial technique in which the lateral angles of the occipital squama are manually approximated slightly exaggerating the posterior convexity of the occiput and taking the cranium into sustained extension.

**counterstrain (CS),** 1. A system of diagnosis and treatment that considers the dysfunction to be a continuing, inappropriate strain reflex, which is inhibited by applying a position of mild strain in the direction exactly opposite to that of the reflex; this is accomplished by specific directed positioning about the point of tenderness to achieve the desired therapeutic response. 2. Australian and French use: Jones technique, (correction spontaneous by position), spontaneous release by position. 3. Developed by Lawrence Jones, DO.

**cranial treatment (CR),** See *primary respiratory mechanism*. See *osteopathy in the cranial field*.

**CV-4,** Abbreviation for compression of the fourth ventricle. See *osteopathic manipulative treatment, compression of the fourth ventricle*.

**Dalrymple treatment,** See *osteopathic manipulative treatment, pedal pump*.

**direct method (D/DIR),** an osteopathic treatment strategy by which the restrictive barrier is engaged and a final activating force is applied to correct somatic dysfunction.

**exaggeration method,** an osteopathic treatment strategy by which the dysfunctional component is carried away from the restrictive barrier and beyond the range of voluntary motion to a point of palpably increased tension.

**exaggeration technique,** an indirect procedure that involves carrying the dysfunctional part away from the restrictive barrier, then applying a high velocity/low amplitude force in the same direction.

**facilitated oscillatory release technique (FOR),** 1. A technique intended to normalize neuromuscular function by applying a manual oscillatory force, which may be combined with any other ligamentous

or myofascial technique. 2. A refinement of a long-standing use of oscillatory force in osteopathic diagnosis and treatment as published in early osteopathic literature. 3. A technique developed by Zachary Comeaux, DO.

**facilitated positional release (FPR)**, a system of indirect myofascial release treatment. The component region of the body is placed into a neutral position, diminishing tissue and joint tension in all planes, and an activating force (compression or torsion) is added. 2. A technique developed by Stanley Schiowitz, DO.

**fascial release treatment**, See *osteopathic manipulative treatment, myofascial release*.

**fascial unwinding**, a manual technique involving constant feedback to the osteopathic practitioner who is passively moving a portion of the patient's body in response to the sensation of movement. Its forces are localized using the sensations of ease and bind over wider regions.

**functional method**, an indirect treatment approach that involves finding the dynamic balance point and one of the following: applying an indirect guiding force, holding the position or adding compression to exaggerate position and allow for spontaneous readjustment. The osteopathic practitioner guides the manipulative procedure while the dysfunctional area is being palpated in order to obtain a continuous feedback of the physiologic response to induced motion. The osteopathic practitioner guides the dysfunctional part so as to create a decreasing sense of tissue resistance (increased compliance).

**Galbreath treatment**, See *osteopathic manipulative treatment, mandibular drainage*.

**hepatic pump**, rhythmic compression applied over the liver for purposes of increasing blood flow through the liver and enhancing bile and lymphatic drainage from the liver.

**high velocity/low amplitude technique (HVLA)**, An osteopathic technique employing a rapid, therapeutic force of brief duration that travels a short distance within the anatomic range of motion of a joint, and that engages the restrictive barrier in one or more planes of motion to elicit release of restriction. Also known as thrust technique.

**Hoover technique**, 1. A form of functional method. 2. Developed by H.V. Hoover, DO. See also *osteopathic manipulative treatment, functional technique*.

**indirect method (I/IND)**, a manipulative technique where the restrictive barrier is disengaged and the dysfunctional body part is moved away from the restrictive barrier until tissue tension is equal in one or all planes and directions.

**inhibitory pressure technique**, the application of steady pressure to soft tissues to reduce reflex activity and produce relaxation.

**integrated neuromusculoskeletal release (INR)**, a treatment system in which combined procedures are designed to stretch and reflexly release patterned soft tissue and joint-related restrictions. Both direct and indirect methods are used interactively.

**Jones technique**, See *osteopathic manipulative treatment, counterstrain*.

**ligamentous articular strain technique (LAS)**, 1. A manipulative technique in which the goal of treatment is to balance the tension in opposing ligaments where there is abnormal tension present. 2. A set of myofascial release techniques described by Howard Lippincott, DO, and Rebecca Lippincott, DO. 3. Title of reference work by Conrad Speece, DO, and William Thomas Crow, DO.

**liver pump**, See *hepatic pump*

**lymphatic pump**, 1. A term used to describe the impact of intrathoracic pressure changes on lymphatic flow. This was the name originally given to the thoracic pump technique before the more extensive physiologic effects of the technique were recognized. 2. A term coined by C. Earl Miller, DO.

**mandibular drainage technique**, soft tissue manipulative technique using passively induced jaw motion to effect increased drainage of middle ear structures via the eustachian tube and lymphatics.

**mesenteric release technique (mesenteric lift)**, technique in which tension is taken off the attachment of the root of the mesentery to the posterior body wall. Simultaneously, the abdominal contents are compressed to enhance venous and lymphatic drainage from the bowel.

**muscle energy**, 1. A system of diagnosis and treatment in which the patient voluntarily moves the body as specifically directed by the osteopathic practitioner. This directed patient action is from a precisely controlled position against a defined resistance by the osteopathic practitioner. 2. Refers to a concept first used by Fred L. Mitchell, Sr, DO, originally called muscle energy treatment.

**myofascial release (MFR)**, a system of diagnosis and treatment first described by Andrew Taylor Still and his early students, which engages continual palpatory feedback to achieve release of myofascial tissues.

**direct MFR**, a myofascial tissue restrictive barrier is engaged for the myofascial tissues and the tissue is loaded with a constant force until tissue release occurs.

**indirect MFR**, the dysfunctional tissues are guided along the path of least resistance until free movement is achieved.

**myofascial technique**, any technique directed at the muscles and fascia. See also *osteopathic manipulative treatment, myofascial release*. See also *osteopathic manipulative treatment, soft tissue technique*.

**myotension**, a system of diagnosis and treatment that uses muscular contractions and relaxations under resistance of the osteopathic practitioner to relax, strengthen or stretch muscles, or mobilize joints.

**Osteopathy in the Cranial Field (OCF)**, 1. A system of diagnosis and treatment by an osteopathic practitioner using the primary respiratory mechanism and balanced membranous tension. See also *primary respiratory mechanism*. 2. Refers to the system of diagnosis and treatment first described by William G. Sutherland, DO. 3. Title of reference work by Harold Magoun, Sr, DO.

**passive method**, based on techniques in which the patient refrains from voluntary muscle contraction.

**pedal pump**, a venous and lymphatic drainage technique applied through the lower extremities; also called the pedal fascial pump or Dalrymple treatment.

**percussion vibrator technique**, 1. A manipulative technique involving the specific application of mechanical vibratory force to treat somatic dysfunction. 2. An osteopathic manipulative technique developed by Robert Fulford, DO.

**positional technique**, a direct segmental technique in which a combination of leverage, patient ventilatory movements and a fulcrum are used to achieve mobilization of the dysfunctional segment. May be combined with springing or thrust technique.

**progressive inhibition of neuromuscular structures (PINS)**, 1. A system of diagnosis and treatment in which the osteopathic practitioner

locates two related points and sequentially applies inhibitory pressure along a series of related points. 2. Developed by Dennis Dowling, DO.

**range of motion technique**, active or passive movement of a body part to its physiologic or anatomic limit in any or all planes of motion.

**soft tissue (ST)**, A system of diagnosis and treatment directed toward tissues other than skeletal or arthrodial elements.

**soft tissue technique**, a direct technique that usually involves lateral stretching, linear stretching, deep pressure, traction and/or separation of muscle origin and insertion while monitoring tissue response and motion changes by palpation. Also called myofascial treatment.

**Spencer technique**, a series of direct manipulative procedures to prevent or decrease soft tissue restrictions about the shoulder. See also *osteopathic manipulative treatment (OMT)*, *articular treatment (ART)*

**splenic pump technique**, rhythmic compression applied over the spleen for the purpose of enhancing the patient's immune response. See also *osteopathic manipulative treatment (OMT)*, *lymphatic pump*.

**spontaneous release by positioning**, See *osteopathic manipulative treatment, counterstrain*.

**springing technique**, a low velocity/moderate amplitude technique where the restrictive barrier is engaged repeatedly to produce an increased freedom of motion. See also *osteopathic manipulative treatment, articular treatment system*.

**Still Technique**, 1. Characterized as a specific non-repetitive articular method that is indirect then direct. 2. Attributed to A.T. Still. 3. A term coined by Richard Van Buskirk, DO, PhD.

**Strain-Counterstrain®**, An osteopathic system of diagnosis and indirect treatment in which the patient's somatic dysfunction, diagnosed by (an) associated myofascial tenderpoint(s), is treated by using a passive position, resulting in spontaneous tissue release and at least 70 percent decrease in tenderness. 2). Developed by Lawrence H. Jones, DO, in 1955. See *osteopathic treatments, counterstrain*.

**thoracic pump**, 1. A technique that consists of intermittent compression of the thoracic cage. 2. Developed by C. Earl Miller, DO

**thrust technique (HVLA)**, See *osteopathic manipulative treatment*,

*high velocity/low amplitude technique (HVLA)*.

**toggle technique**, short lever technique using compression and shearing forces.

**traction technique**, a procedure of high or low amplitude in which the parts are stretched or separated along a longitudinal axis with continuous or intermittent force.

**v-spread**, technique using forces transmitted across the diameter of the skull to accomplish sutural gapping.

**ventral techniques**, See *osteopathic manipulative treatment, visceral manipulation*.

**visceral manipulation (VIS)**, a system of diagnosis and treatment directed to the viscera to improve physiologic function. Typically, the viscera are moved toward their fascial attachments to a point of fascial balance. Also called ventral techniques.

**osteopathic musculoskeletal evaluation:** The osteopathic musculoskeletal evaluation provides information regarding the health of the patient. Utilizing the concepts of body unity, self-regulation and structure-function interrelationships, the osteopathic physician uses data from the musculoskeletal evaluation to assess the patient's status and develop a treatment plan. (AOA House of Delegates)

**osteopathic philosophy:** a concept of health care supported by expanding scientific knowledge that embraces the concept of the unity of the living organism's structure (anatomy) and function (physiology). Osteopathic philosophy emphasizes the following principles: 1. The human being is a dynamic unit of function. 2. The body possesses self-regulatory mechanisms that are self-healing in nature. 3. Structure and function are interrelated at all levels. 4. Rational treatment is based on these principles.

**osteopathic physician:** a person with full unlimited medical practice rights who has achieved the nationally recognized academic and professional standards within his or her country to practice diagnosis and treatment based upon the principles of osteopathic philosophy. Individual countries establish the national academic and professional standards for osteopathic physicians practicing within their countries.

**osteopathic postural examination:** The part of the osteopathic musculoskeletal examination that focuses on the static and dynamic responses of the body to gravity while in the erect position.

**osteopathic practitioner:** Refers to an osteopath, an osteopathic physician or

an allopathic physician who has been trained in osteopathic principles, practices and philosophy.

**osteopathic structural examination:** The examination of a patient by an osteopathic practitioner with emphasis on the neuromusculoskeletal system including palpatory diagnosis for somatic dysfunction and viscerosomatic change within the context of total patient care. The examination is concerned with finding somatic dysfunction in all parts of the body, and is performed with the patient in multiple positions to provide static and dynamic evaluation.

**osteopathy (osteopathic medicine):** A complete system of medical care with a philosophy that combines the needs of the patient with current practice of medicine, surgery and obstetrics. Emphasizes the interrelationship between structure and function, and has an appreciation of the body's ability to heal itself.

## P

**palpation:** The application of the fingers to the surface of the skin or other tissues, using varying amounts of pressure, to selectively determine the condition of the parts beneath.

**palpatory diagnosis:** A term used by osteopathic practitioners to denote the process of palpating the patient to evaluate the structure and function of the neuromusculoskeletal and visceral systems.

**palpatory skills:** Sensory skills used in performing palpatory diagnosis and osteopathic manipulative treatment.

**passive method:** See *osteopathic manipulative treatment, passive method*.

**passive motion:** See *motion, passive motion*.

**patient cooperation:** Voluntary movement by the patient (on instruction from the osteopathic practitioner) to assist in the palpatory diagnosis and treatment process.

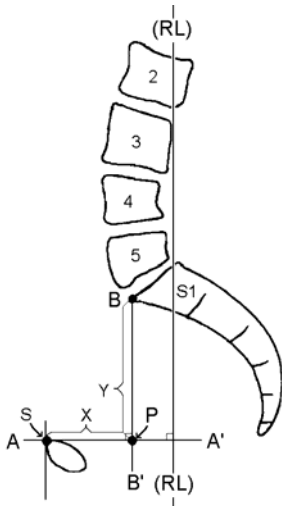
**pedal pump:** See *osteopathic manipulative treatment, pedal pump*.

**pelvic bone:** See *hip bone*.

**pelvic declination (pelvic unleveling):** Pelvic rotation about an anterior-posterior (A-P) axis.

**pelvic index (PI):** Represents a ratio of the measurements determined from postural radiograph: One (y) beginning from a vertical line originating at the sacral promontory to the intersection with the horizontal line from the anterior-superior position of the pubic bone. The second measurement (x) is

along this same horizontal line. Normal values are age-related and increase in subjects with sagittal plane postural decompensation. Pelvic index (PI) equals  $x/y$ . (Fig. 24)



**Figure 24. Pelvic index (PI).** (Modified from Kuchera WA, Kuchera ML, *Osteopathic Principles in Practice*, Greyden Press, Columbus, OH, 1994:263).

**pelvic rotation:** Movement of the entire pelvis in a relatively horizontal plane about a vertical (longitudinal) axis.

**pelvic sideshift:** Deviation of the pelvis to the right or left of the central vertical axis as translation occurs along the horizontal (z) axis. Usually observed in the standing position.

**pelvic tilt:** Pelvic rotation about a transverse (horizontal) axis (forward or backward tilt) or about an anterior-posterior axis (right or left side tilt).

**pelvis:** Within the context of structural diagnosis, the pelvis is made up of the right and left innominates, (hip bone or os coxae) the sacrum and coccyx.

**percussion vibrator technique:** See *osteopathic manipulative treatment, percussion vibrator technique*.

**pétrissage:** Deep kneading or squeezing action to express swelling.

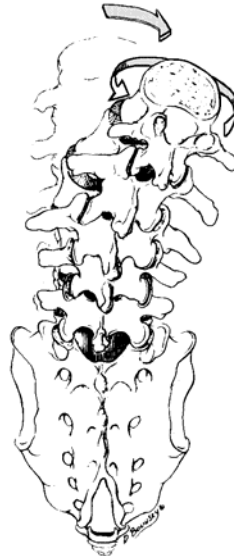**physiologic barrier:** See *barrier, physiologic barrier*.

**physiologic motion:** See *motion, physiologic motion*.

**physiologic motion of the spine:** The three major principles of physiologic motion are:

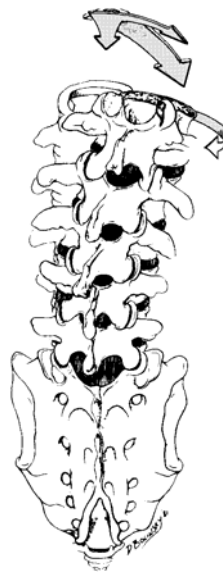**I.** When the thoracic and lumbar spine are in a neutral position (easy normal; See *neutral Fig. 23*), the coupled motions of sidebending and rotation for a group of vertebrae are such that sidebending and rotation occur in

opposite directions (with rotation occurring toward the convexity). (Fig. 25). See *somatic dysfunction, type I s.d.*



**Figure 25. Physiologic motion of the thoracic or lumbar spine resulting from a neutral spinal position (Type I motion).**

**II.** When the thoracic and lumbar spine are sufficiently forward or backward bent (non-neutral), the coupled motions of sidebending and rotation in a single vertebral unit occur in the same direction. (Fig. 26) See *somatic dysfunction, type II, s.d.*



**Figure 26. Physiologic motion of the thoracic or lumbar spine resulting from a non-neutral spinal position (Type II motion).**

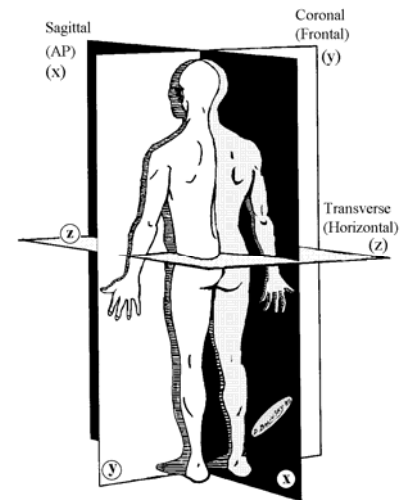
**III.** 1. Initiating motion of a vertebral segment in any plane of motion will modify the movement of that segment in other planes of motion.

2. Principles I and II of thoracic and lumbar spinal motion described by Harrison H. Fryette, DO (1918), Principle III was described by C.R. Nelson, DO (1948). See *rotation*. See also *rotation of vertebra*.

**plagiocephaly:** An asymmetric condition of the head.

**plane:** A flat surface determined by the position of three points in space. Any of a number of imaginary surfaces passing through the body and dividing it into segments. (Fig. 27)

**AP plane,** See *plane, sagittal plane*.



**Figure 27. Planes of the body.**

**coronal plane (frontal plane),** a plane passing longitudinally through the body from one side to the other, and dividing the body into anterior and posterior portions.

**frontal plane,** See *plane, coronal plane*.

**horizontal plane,** See *plane, transverse plane*.

**sagittal plane,** a plane passing longitudinally through the body from front to back and dividing it into right and left portions. The median or midsagittal plane divides the body into approximately equal right and left portions.

**transverse plane (horizontal plane),** a plane passing horizontally through the body perpendicular to the sagittal and frontal planes, dividing the body into upper and lower portions.

**plastic deformation:** A non-recoverable deformation. See also *elastic deformation*.

**plasticity:** Ability to retain a shape attained by deformation. See also *elasticity*. See also *viscosity*.

**positional technique:** See *osteopathic manipulative treatment, positional technique*.

**posterior component:** A positional descriptor used to identify the side of reference when rotation of a vertebral segment has occurred. In a condition of right rotation, the right side is the posterior component. It usually refers to a prominent vertebral transverse process. See also *anterior component*.

**posterior nutation:** See *counternutation*.

**post-isometric relaxation:** Immediately following an isometric contraction, the neuromuscular apparatus is in a refractory state during which enhanced passive stretching may be performed. The osteopathic practitioner may take up the myofascial slack during the relaxed refractory period.

**postural axis:** See *sacral motion axis, postural axis*.

**postural balance:** A condition of optimal distribution of body mass in relation to gravity.

**postural decompensation:** Distribution of body mass away from ideal when postural homeostatic mechanisms are overwhelmed. It occurs in all cardinal planes, but is classified by the major plane(s) affected. See *planes of the body* (Fig. 27).

**coronal plane p. d.,** causes scoliotic changes.

**horizontal plane p. d.,** may cause postural changes where part or all of the body rotates to the right or left. When viewed from the right or left sides, alignment appears asymmetrical.

**sagittal plane p. d.,** causes kyphotic and/or lordotic changes.

**postural imbalance:** A condition in which ideal body mass distribution is not achieved.

**posture:** Position of the body. The distribution of body mass in relation to gravity.

**primary machinery of life:** The neuromusculoskeletal system. A term used to denote that body parts act together to transmit and modify force and motion through which man acts out his life. This integration is achieved via the central nervous system acting in response to continued sensory input from the internal and external environment. 2. A term coined by I.M. Korr, PhD.

**primary respiratory mechanism:** 1. A conceptual model that describes a process involving five interactive, involuntary functions: (1). The inherent motility of the brain and spinal cord. (2). Fluctuation of the cerebrospinal fluid. (3). Mobility of the intracranial and intraspinal membranes. (4). Articular mobility of the cranial bones. (5). Mobility of the sacrum between the ilia (pelvic bones) that is interdependent with the motion at the sphenobasilar synchondrosis.

This mechanism refers to the presumed inherent (primordial) driving mechanism of internal respiration as opposed to the cycle of diaphragmatic respiration (inhalation and exhalation). It further refers to the innate interconnected movement of every tissue and structure of the body. Optimal health promotes optimal function and the inherent function of this interdependent movement can be negatively altered by trauma, disease states or other pathology.

2. This mechanism was first described by William G. Sutherland, DO, and is thought to affect cellular respiration and other body processes. In the original definition, the following descriptions were given:

**primary,** because it is directly concerned with the internal tissue respiration of the central nervous system.

**respiratory,** because it further concerns the physiological function of the interchange of fluids necessary for normal metabolism and biochemistry, not only of the central nervous system, but also of all body cells.

**mechanism,** because all the constituent parts work together as a unit carrying out this fundamental physiology. See also *osteopathic manipulative treatment (OMT), osteopathy in the cranial field*

**prime mover:** A muscle primarily responsible for causing a specific joint action.

**progressive inhibition of neuromuscular structures (PINS):** See *osteopathic manipulative treatment, Progressive Inhibition of Neuromuscular Structures*.

**prolotherapy:** See *sclerotherapy*.

**pronation:** In relation to the anatomical position, as applied to the hand, rotation of the forearm in such a way that the palmar surface turns backward (internal rotation) in relationship to the anatomical position. Applied to the foot: a combination of eversion and abduction movements taking place in the tarsal and metatarsal joints,

resulting in lowering of the medial margin of the foot. See also *supination*.

**prone:** Lying face downward (*Dorland's*).

**psaos syndrome:** A painful low back condition characterized by hypertonicity of psoas musculature. The syndrome consists of a constellation of typically related signs and symptoms:

**typical posture,** flexion at the hip and sidebending of the lumbar spine to the side of the most hypertonic psoas muscle.

**typical gait,** Trendelenburg gait.

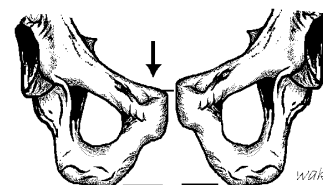
**typical pain pattern,** low back pain frequently accompanied by pain on the lateral aspect of the lower extremity extending no lower than the knee.

**typical associated somatic dysfunctions,** as a long restrictor muscle, psoas hypertonicity is frequently associated with flexed dysfunctions of the upper lumbar, extended dysfunction of L5, and variable sacral and innominate dysfunctions. Tender points typically are found in the ipsilateral iliacus and contralateral piriformis muscles.

**pubic bone, somatic dysfunctions of:**

**anterior pubic shear,** a somatic dysfunction in which one pubic bone is displaced anteriorly with relation to its normal mate.

**inferior pubic shear,** a somatic dysfunction in which one pubic bone is displaced inferiorly with relation to its normal mate. (Fig. 28)



Seated flexion test = R(+)

Figure 28. Right inferior pubic shear.

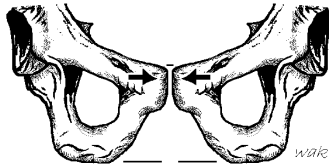
**posterior pubic shear,** a somatic dysfunction in which one pubic bone is displaced posteriorly with relation to its normal mate.

**pubic abduction,** See *pubic gapping*.

**pubic adduction,** See *pubic compression*.

**pubic compression (pubic adduction),** a somatic dysfunction in which the pubic bones are forced toward each other at the pubic symphysis. This dysfunction is characterized by tenderness to palpation over the pubic symphysis, lack of apparent asymmetry, but

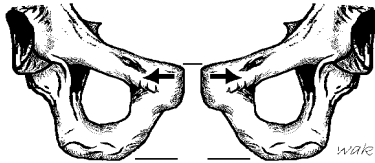
associated with restricted motion of the pelvic ring. (Fig. 29)



Seated flexion test = Bilaterally (+)  
(False negative)

Figure 29. Pubic compression.

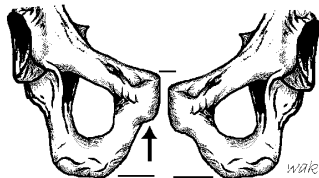
**pubic gapping (pubic abduction)**, a somatic dysfunction in which the pubic bones are pulled away from each other at the pubic symphysis. This dysfunction is frequently seen in women following childbirth. (Fig. 30)



Seated flexion test = Bilaterally (+)  
(False negative)

Figure 30. Pubic gapping ( pubic abduction)

**superior pubic shear**, a somatic dysfunction in which one pubic bone is displaced superiorly with relation to its normal mate. (Fig. 31)



Seated flexion test = R(+)

Figure 31. Right superior pubic shear.

**pubic symphysis, somatic dysfunctions of:** See *pubic bone, somatic dysfunctions of*.

**pump handle rib motion:** See *rib motion, pump handle motion*.

## R

**range of motion technique:** See *osteopathic manipulative treatment, range of motion technique*.

**reciprocal inhibition:** The inhibition of antagonist muscles when the agonist is stimulated. See also *laws, Sherrington's*.

**reciprocal tension membrane:** The intracranial and spinal dural membrane including the falx cerebri, falx cerebelli, tentorium and spinal dura.

**red reflex:** See *reflex, red r.*

**reflex:** An involuntary nervous system response to a sensory input. The sum total of any particular involuntary activity. See also *Chapman reflexes*.

**cephalogyric reflex,** See *oculocephalogyric r.*

**cervicolumbar r.,** automatic contraction of the lumbar paravertebral muscles in response to contraction of postural muscles in the neck.

**conditioned r.,** one that does not occur naturally in the organism or system, but that is developed by regular association of some physiological function with a related outside event.

**myotatic r.,** tonic contraction of the muscles in response to a stretching force, due to stimulation of muscle receptors (e.g.: deep tendon reflex).

**oculocephalogyric r.,** (oculogyric reflex, cephalogyric reflex), automatic movement of the head that leads or accompanies movement of the eyes.

**oculogyric reflex.** See *oculocephalogyric r.*

**red r.,** 1. The erythematous biochemical reaction (reactive hyperemia) of the skin in an area that has been stimulated mechanically by friction. The reflex is greater in degree and duration in an area of acute somatic dysfunction as compared to an area of chronic somatic dysfunction. It is a reflection of the segmentally related sympatheticotonia commonly observed in the paraspinal area. 2. A red glow reflected from the fundus of the eye when a light is cast upon the retina.

**somatosomatic r.,** localized somatic stimuli producing patterns of reflex response in segmentally related somatic structures.

**somatovisceral r.,** localized somatic stimulation producing patterns of reflex response in segmentally related visceral structures.

**viscerosomatic r.,** localized visceral stimuli producing patterns of reflex response in segmentally related somatic structures.

**viscerovisceral r.,** localized visceral stimuli producing patterns of reflex response in segmentally related visceral structures.

**regenerative injection therapy (RIT):** See *sclerotherapy*.

**region:** 1. An anatomical division of the body defined either by natural,

functional or arbitrary boundaries. 2. Body areas for the diagnosis and coding of somatic dysfunction as defined in the International Classification of Diseases (currently ICD-9 CM) using the codes:

739.0 somatic dysfunction, head  
739.1 somatic dysfunction, cervical  
739.2 somatic dysfunction, thoracic  
739.3 somatic dysfunction, lumbar  
739.4 somatic dysfunction, sacrum  
739.5 somatic dysfunction, pelvis  
739.6 somatic dysfunction, lower extremity  
739.7 somatic dysfunction, upper extremity  
739.8 somatic dysfunction, rib cage  
739.9 somatic dysfunction, abdomen/other

See also *transitional region*.

**regional extension:** See *extension, regional extension*.

**regional motor inputs:** Motion initiated by an osteopathic practitioner through body contact and vector input that produces a specific response at each segment in the mobile system.

**resilience:** Property of returning to the former shape or size after mechanical distortion. See also *elasticity*. See also *plasticity*.

**respiratory axis of the sacrum:** See *sacral motion axis, superior transverse axis*.

**respiratory cooperation:** An osteopathic practitioner-directed inhalation and/or exhalation by the patient to assist the manipulative treatment process.

**restriction:** A resistance or impediment to movement. For joint restriction, See *barrier (motion barrier)*.

**retrolisthesis:** Posterior displacement of one vertebra relative to the one immediately below.

**rib lesion:** (Archaic) See *rib somatic dysfunction*.

**rib motion:**

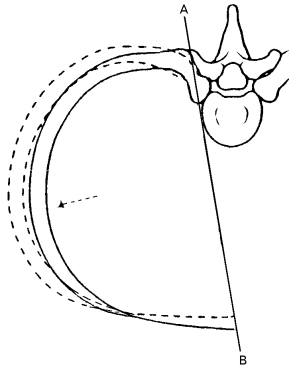
**axis of rib motion,** an imaginary line through the costotransverse and the costovertebral articulations of the rib.

**anteroposterior rib axis,** (Fig. 32) See also *bucket handle rib motion*.

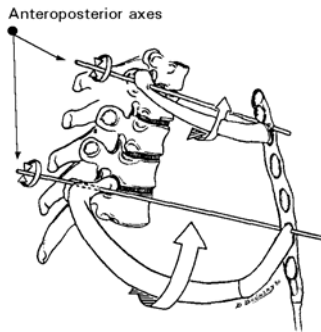
**bucket handle motion,** movement of the ribs during respiration such that with inhalation, the lateral aspect of the rib moves cephalad resulting in an increase of transverse diameter of the thorax. This type of rib motion is predominantly found in lower ribs, increasing in motion from the upper to the lower ribs. (Fig. 33) See also *rib motion, axis of*. See also *rib motion, pump handle*.

**caliper rib motion,** Rib motion of ribs 11 and 12 characterized by single joint





**Figure 32. The functional anterior-posterior rib axis.**



**Figure 33. Bucket handle rib motion.**

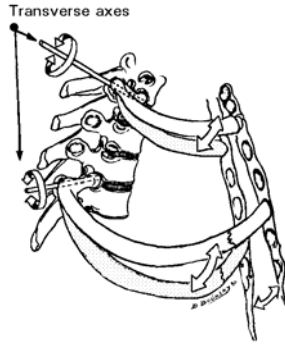
motion; analogous to internal and external rotation.

**exhalation rib restriction**, involves a rib or group of ribs that first stops moving during exhalation. The key rib is the bottom rib in the group. See also *rib somatic dysfunction, inhalation rib dysfunction*.

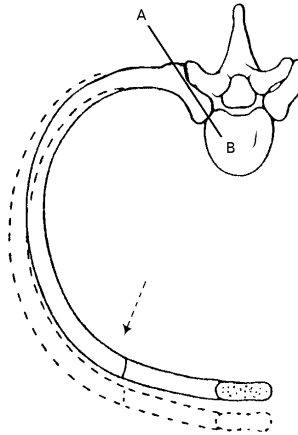
**inhalation rib restriction**, involves a rib or group of ribs that first stops moving during inhalation. The key rib is the top rib in the group. See also *rib somatic dysfunction, exhalation rib dysfunction*.

**pump handle motion**, movement of the ribs during respiration such that with inhalation the anterior aspect of the rib moves cephalad and causes an increase in the anteroposterior diameter of the thorax. This type of rib motion is found predominantly in the upper ribs, decreasing in motion from the upper to the lower ribs. (Fig. 34) See *rib motion, axis of*. See also *rib motion, bucket handle motion*.

**transverse rib axis**, (Fig. 35) See *rib motion, pump handle rib motion*



**Figure 34. Pump handle rib motion.**



**Figure 35. The functional transverse rib axis.**

*inhalation*. See also *rib motion, inhalation rib restriction*. See also *rib motion, exhalation rib restriction*.

**rib somatic dysfunction**: A somatic dysfunction in which movement or position of one or several ribs is altered or disrupted. For example, an elevated rib is one held in a position of inhalation such that motion toward inhalation is freer, and motion toward exhalation is restricted. A depressed rib is one held in a position of exhalation such that motion toward exhalation is freer and there is a restriction in inhalation. See also *rib motion, inhalation rib restriction*. See also *rib motion, exhalation rib restriction*.

**exhalation rib dysfunction, 1.** Somatic dysfunction characterized by a rib being held in a position of exhalation such that motion toward exhalation is more free and motion toward inhalation is restricted. Synonyms: *inhalation rib restriction depressed rib*. 2. An anterior rib tender point in counterstrain. See also *rib motion, inhalation rib restriction*.

**inhalation rib dysfunction**, A somatic dysfunction characterized by a rib

being held in a position of inhalation such that motion toward inhalation is more free and motion toward exhalation is restricted. Synonyms: *inhaled rib, anterior rib, elevated rib*,

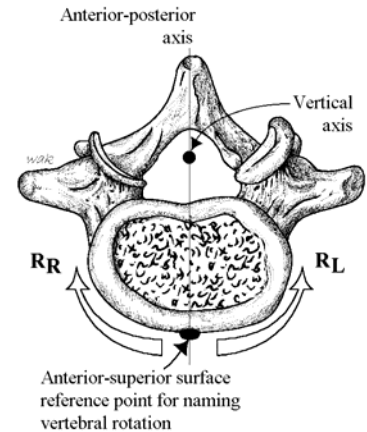
**ropiness**: A tissue texture abnormality characterized by a cord-like feeling. See also *tissue texture abnormality*.

**rotation**: Motion about an axis.

**rotation dysfunction of the sacrum**, See *sacrum, somatic dysfunctions of*.

**rotation of sacrum**, movement of the sacrum about a vertical (y) axis (usually in relation to the innominate bones).

**rotation of vertebra**, movement about the anatomical vertical axis (y axis) of a vertebra; named by the motion of a midpoint on the anterior-superior surface of the vertebral body. (Fig. 36)



**Figure 36. Rotation of a vertebra (lumbar).**

**rule of threes**: A method to locate the approximate position of the transverse process (TP) of a thoracic segment by using the location of the spinous process (SP) of that same vertebra. The relationship is as follows:

- T1 to T3, TP is at the same level as tip of the SP
- T4 to T6, TP is one half vertebral level above the tip of the SP
- T7 to T9, TP is one full vertebral level above the tip of the SP
- T10, TP is one full vertebral level above the tip of the SP
- T11, TP is one half vertebral level above the tip of the SP
- T12, TP is at the same level as tip of the SP.

S

**sacral base:** 1. In osteopathic palpation, the uppermost posterior portion of the sacrum. 2. The most cephalad portion of the first sacral segment (*Gray's Anatomy*).

**sacral base anterior:** See *sacrum, somatic dysfunctions of, bilateral sacral flexion*.

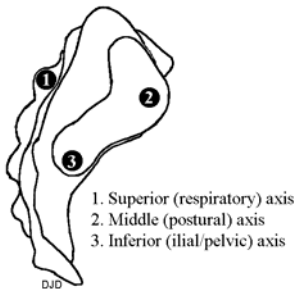
**sacral base declination (unleveling):** With the patient in a standing or seated position, any deviation of the sacral base from the horizontal in a coronal plane. Generally, the rotation of the sacrum about an anterior-posterior axis.

**sacral base posterior:** See *sacrum, somatic dysfunctions of, bilateral sacral flexion*.

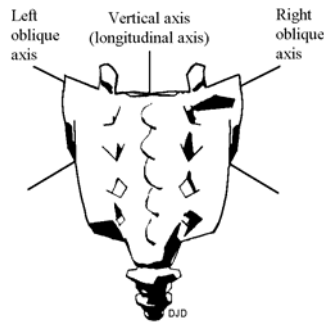
**sacral base unleveling:** See *sacral base declination*.

**sacralization:** See *transitional vertebrae, sacralization*.

**sacral movement axis:** any of the hypothetical axes for motion of the sacrum. (**Fig. 37, Fig. 38**)



**Figure 37. Sacral transverse axes (lateral view).**



**Figure 38. Axes of sacral motion (posterior view).**

**anterior-posterior (x) axis,** axis formed at the line of intersection of a sagittal and transverse plane.

**inferior transverse axis (innominate),** the hypothetical functional axis of sacral motion that passes from side to side on a line through the inferior auricular surface of the sacrum and ilia, and represents the axis for movement of the ilia on the sacrum. 2. A term described by Fred Mitchell, Sr, DO. (**Fig. 37**)

**longitudinal axis,** the hypothetical axis formed at the line of intersection of the midsagittal plane and a coronal plane, See *sacral motion axis, vertical (y) axis longitudinal*. (**Fig. 38**)

**middle transverse axis (postural),** the hypothetical functional axis of sacral nutation/counternutation in the standing position, passing horizontally through the anterior aspect of the sacrum at the level of the second sacral segment. 2. A term described by Fred Mitchell, Sr, DO. (**Fig. 37**)

**oblique axis (diagonal),** a hypothetical functional axis from the superior area of a sacroiliac articulation to the contralateral inferior sacroiliac articulation. It is designated as right or left relevant to its superior point of origin. 2. A term described by Fred Mitchell, Sr, DO. (**Fig. 38**)

**postural axis,** See *sacrum, middle transverse axis (postural)*. (**Fig. 37**)

**respiratory axis,** See *sacrum, superior transverse axis (respiratory)*. (**Fig. 37**)

**superior transverse axis (respiratory),** the hypothetical transverse axis about which the sacrum moves during the respiratory cycle. It passes from side to side through the articular processes posterior to the point of attachment of the dura at the level of the second sacral segment. Involuntary sacral motion occurs as part of the cranosacral mechanism, and is believed to occur about this axis. 2. A term described by Fred Mitchell, Sr, DO. (**Fig. 37**)

**transverse (z) axes,** axes formed by intersection of the coronal and transverse planes about which nutation/counternutation occurs. (**Fig. 37**)

**vertical (y) axis (longitudinal),** the axis formed by the intersection of the sagittal and coronal planes. (**Fig. 38**)

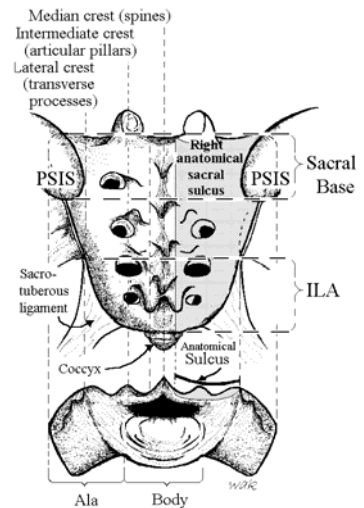
**sacral somatic dysfunction:** See *sacrum, somatic dysfunctions of*.

**sacral sulcus:** A depression just medial to the posterior superior iliac spine (PSIS) as a result of the spatial relationship of the PSIS to the dorsal aspect of the sacrum. (**Fig. 39, Fig. 40**)

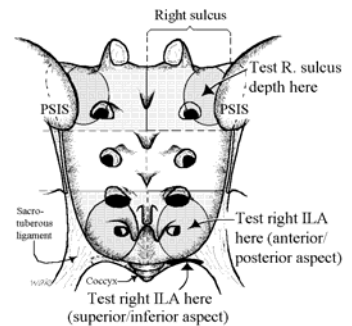
**sacral torsion:** 1. A physiologic function occurring in the sacrum during ambulation and forward bending. 2. A sacral somatic dysfunction around an oblique axis in which a torque occurs between the sacrum and innominates. The L5 vertebra rotates in the opposite direction of the sacrum. 3. If the L5 does not rotate opposite to the sacrum, L5 is termed maladapted. 4. Other terms for this maladaptation include: rotations about an oblique axis, anterior or posterior sacrum and a torsion with a non-compensated L5 (Archaic use). See also *sacrum, somatic dysfunctions of*.

**sacroiliac motion:** Motion of the sacrum in relationship to the innominate(s) (ilium/ilia).

**sacrum, inferior lateral angle (ILA) of:** The point on the lateral surface of the sacrum where it curves medially to the body of the fifth sacral vertebrae (*Gray's Anatomy*). (**Fig. 39, Fig. 40**)



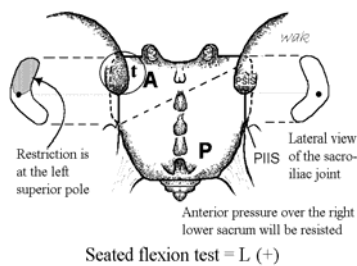
**Figure 39. Anatomical sacral divisions.**



**Figure 40. Clinical sacral divisions: sacral sulcus at the base, and inferior lateral angles (ILA).**

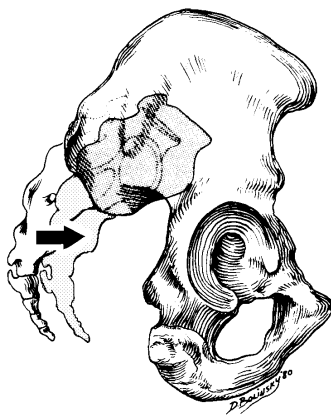
**sacrum, somatic dysfunctions of:** any of a group of somatic dysfunctions involving the sacrum. These may be the result of restriction of normal physiologic motion or trauma to the sacrum. See also *T.A.R.T.*

**anterior sacrum,** a positional term based on the Strachan model referring to sacral somatic dysfunction in which the sacral base has rotated anterior and sidebent to the side opposite the rotation. The upper limb (pole) of the SI joint has restricted motion and is named for the side on which forward rotation had occurred. Tissue texture changes are found at the deep sulcus. (The motion characteristics of L5 are not described.) (Fig. 41)



**Figure 41. Anterior sacrum left.** Motion of L5 is not described. There is tissue texture change (t) over the left sacral base. The superior pole of the left sacroiliac joint is affected and the left sacral base will not move posteriorly when an anterior test pressure is applied over the right lower sacrum.

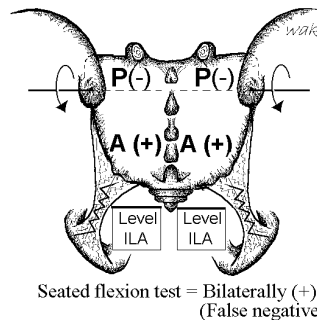
**anterior translated sacrum,** a sacral somatic dysfunction in which the entire sacrum has moved anteriorly (forward) between the ilia. Anterior motion is freer, and the posterior motion is restricted. (Fig. 42)



**Figure 42 Anterior translated sacrum.**

**backward torsions,** 1. A backward sacral torsion is a physiologic rotation of the sacrum around an oblique axis such that the side of the sacral base contralateral to the named axis rotates posteriorly. L5 rotates in the direction opposite to the rotation of the sacral base. 2. Referred to as non-neutral sacral somatic dysfunctions (Archaic use). 3. A term by Fred Mitchell, Sr, DO, that describes the backward torsion as being non-physiologic in terms of the walking cycle.

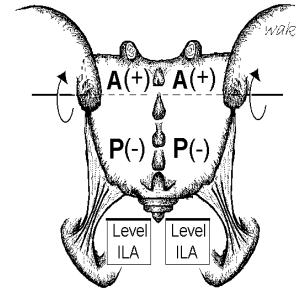
**bilateral sacral extension (sacral base posterior),** 1. A sacral somatic dysfunction that involves rotation of the sacrum about a middle transverse axis such that the sacral base has moved posteriorly relative to the pelvic bones. Backward movement of the sacral base is freer, forward movement is restricted and both sulci are shallow. 2. The reverse of bilateral sacral flexion. (Fig 43)



**Figure 43. Bilateral sacral extension.** (Sacral base posterior)

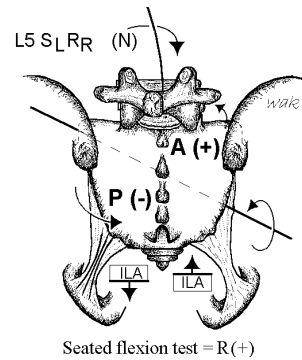
**bilateral sacral flexion (sacral base anterior),** 1. A sacral somatic dysfunction that involves rotation of the sacrum about a middle transverse axis such that the sacral base has moved anteriorly between the pelvic bones. Forward movement of the sacral base is freer, backward movement is restricted and both sulci are deep. 2. The reverse of bilateral sacral extension. (Fig 44)

**forward torsions,** 1. Forward torsion is a physiologic rotation of the sacrum around an oblique axis such that the side of the sacral base contralateral to the named axis glides anteriorly and produces a deep sulcus. L5 rotates in the direction opposite to the rotation of the sacral base. 2. Referred to as neutral sacral somatic dysfunctions (Archaic use) 3. A group of somatic dysfunctions described by Fred Mitchell, Sr, DO, based on the motion cycle of walking.



Seated flexion test = Bilaterally (+)  
(False negative)

**Figure 44. Bilateral sacral flexion.** (Sacral base anterior)



Seated flexion test = R(+)

**Figure 45. Left on left sacral torsion.** (Left on left forward torsion)

**left on left (forward) sacral torsion,** Refers to left rotation torsion around a left oblique axis. (Fig. 45) See also *sacral torsion.*

**left on right (backward) sacral torsion,** Refers to left rotation around a right oblique axis. Findings: The left superior sacral sulcus is posterior or shallow, and the right ILA is anterior or deep. There is a positive seated flexion test on the left. L5 is non-neutral  $S_R R_R$ . Left superior sacral sulcus will be restricted when springing. The lumbosacral spring test is positive, and the sphinx test is positive. (Fig. 46) See *sacral torsion.*

**posterior sacrum,** a positional term based on the Strachan model referring to a sacral somatic dysfunction in which the sacral base has rotated posterior and sidebent to the side opposite to the rotation. The dysfunction is named for the side on which the posterior rotation occurs. The tissue texture changes are found at the lower pole on the side of rotation. (*Foundations*). (The motion characteristics of L5 are not described.) (Fig. 47)

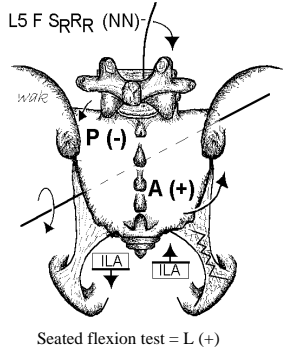


Figure 46. Left on right sacral torsion. (Left on right backward torsion)

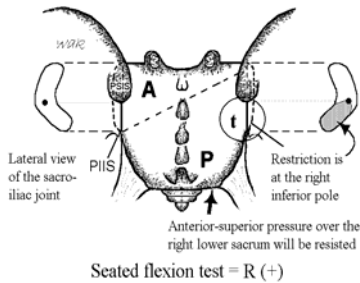


Figure 47. Posterior sacrum right. Motion of L5 is not described. There is tissue texture change (t) over the right sacroiliac joint (SI). The inferior pole of the right SI joint is affected. During motion testing, there is resistance to an anterior/superior test pressure applied over the right lower sacrum.

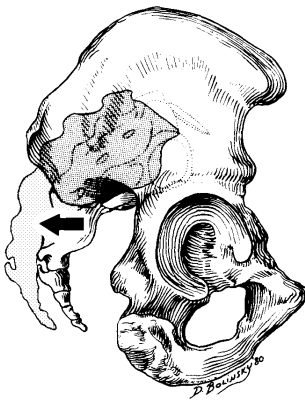


Figure 48. Posterior translated sacrum.

**right on left (backward) sacral torsion**, Refers to right rotation on a left oblique axis. Findings: The right superior sacral sulcus is posterior or

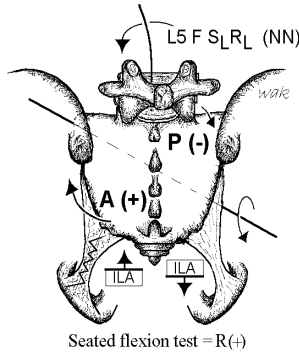


Figure 49. Right on left backward torsion. (Right on left sacral torsion)

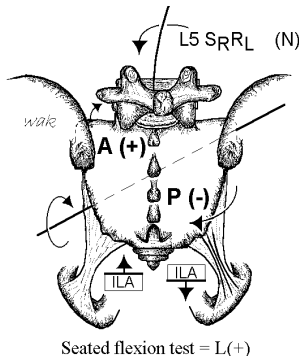


Figure 50. Right on right forward torsion.

shallow, and the left ILA is anterior or deep. The seated flexion test is positive on the right. L5 is non-neutral S<sub>L</sub>R<sub>L</sub>. The right superior sacral sulcus is restricted when springing. The lumbosacral spring test is positive. The sphinx test is positive. (Fig. 49) See *sacral torsion*.

**posterior translated sacrum**, a sacral somatic dysfunction in which the entire sacrum has moved posteriorly (backward) between the ilia. Posterior motion is freer, and anterior motion is restricted. (Fig. 48)

**right on right (forward) torsion**, refers to a right rotation about a right oblique axis. (Fig. 50) See *sacral torsion*.

**rotated dysfunction of the sacrum**, a sacral somatic dysfunction in which the sacrum has rotated about an axis approximating the longitudinal (y) axis. Motion is freer in the direction that rotation has occurred, and is restricted in the opposite direction. (Fig. 51)

**sacral shear**, a complex translational motion of the sacrum in its relationship

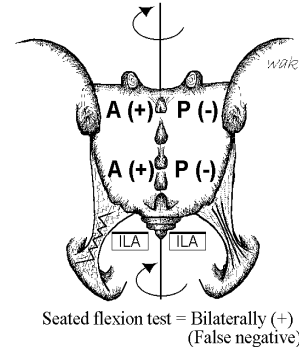


Figure 51. Right rotated dysfunction of the sacrum. (Right rotation about a vertical axis)

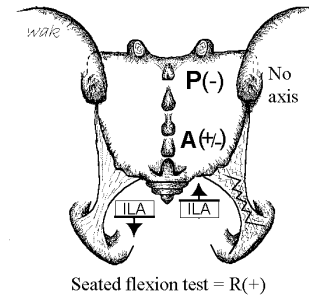


Figure 52. Right unilateral sacral extension. (Right superior sacral

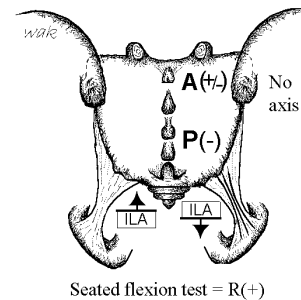


Figure 53. Right unilateral sacral flexion. (Right inferior sacral shear)

to the innominates. (Sometimes described as a sidebending in one direction and rotation in the opposite direction. Alternatively described as a unilateral movement along the arc of the L-shaped curve of the sacroiliac joint.) See also *sacrum, somatic dysfunctions of, unilateral sacral flexion and sacrum, somatic dysfunctions of, unilateral sacral extension*.

**unilateral sacral extension**, is a sacral somatic dysfunction described as a superior shear of one side of the sacrum resulting in a shallow (full) of sacral sulcus and ipsilateral superior-anterior inferolateral angle of the sacrum. (Fig.52) See *sacrum, somatic dysfunctions of, sacral shear*.

**unilateral sacral flexion**, is a sacral somatic dysfunction described as an inferior shear of one side of the sacrum resulting in a deep sacral sulcus and ipsilateral inferior-posterior infero-lateral angle of the sacrum. (Fig. 53) See *sacrum, somatic dysfunctions of, sacral shear*.

**sagittal plane**: See *plane, sagittal plane*.

**scan**: An intermediate detailed examination of specific body regions that have been identified by findings emerging from the initial examination.

**scaphocephaly**: Also called scaphoid head or hatchet head, it is a transverse compression of the cranium with a resultant mid-sagittal ridge.

**scaphoid head**: See also *scaphocephaly*.

**sclerotherapy**: 1. Treatment involving injection of a proliferant solution at the osseous-ligamentous junction. 2. Treatment involving injection of irritating substances into weakened connective tissue areas such as fascia, varicose veins, hemorrhoids, esophageal varices, or weakened ligaments. The intended body's response to the irritant is fibrous proliferation with shortening/strengthening of the tissues injected.

**sclerotome**: 1. The pattern of innervation of structures derived from embryonal mesenchyme (joint capsule, ligament and bone). 2. The area of bone innervated by a single spinal segment. 3. The group of mesenchymal cells emerging from the ventromedial part of a mesodermal somite and migrating toward the notochord. Sclerotomal cells from adjacent somites become merged in inter-somatically located masses that are the primordia of the centra of the vertebrae. (Fig. 54)

**sclerotomal pain**: Deep, dull achy pain associated with tissues derived from a common sclerotome. (Fig. 54)

**scoliosis**: 1. Pathological or functional lateral curvature of the spine. 2. An appreciable lateral deviation in the normally straight vertical line of the spine (*Dorland's*). (Fig. 55)

**screen**: The initial general somatic examination to determine signs of somatic dysfunction in various regions of the body. See also *scan*.

**secondary joint motion**: Involuntary or passive motion of a joint. Also called accessory joint motion.

**segment**: 1. A portion of a larger body or structure set off by natural or arbitrarily established boundaries, often equated with spinal segment. 2. To describe a single vertebrae or a vertebral segment. corresponding to the sites of origin of

rootlets of individual spinal nerves. 3. A portion of the spinal cord

**segmental diagnosis**: The final stage of the spinal somatic examination in which the nature of the somatic problem is detailed at a segmental level. See also *scan*. See also *screen*.

**segmental dysfunction**: dysfunction in a mobile system located at explicit segmental mobile units. Palpable characteristics of a dysfunctional segment are those associated with somatic dysfunction. (See also *STAR, TART and ART*) Responses to regional motor inputs at the dysfunctional segment support the concepts of complete motor asymmetry and mirror-image motion asymmetries.

**segmental mobile unit**: A unit of the human movement system consisting of a bone, with articular surfaces for movement, as well as the adnexal tissues that create movement, allow movement and establish position under motor control.

**segmental motion**: Movement within a vertebral unit described by displacement of a point at the anterior-superior aspect of the superior vertebral body with respect to the segment below.

**sensitization**: Hypothetically, a short-lived (minutes or hours) increase in central nervous system (CNS) response to repeated sensory stimulation that generally follows habituation.

**shear**: An action or force causing or tending to cause two contiguous parts of an articulation to slide relative to each other in a direction parallel to their plane of contact. See also *pubic bone, somatic dysfunctions of, innominates, somatic dysfunctions of, inferior innominate shear*. See also *innominates, somatic dysfunction of, superior innominate shear*. See also *sacrum, somatic dysfunctions of, sacral shear*.

**Sherrington law**: See *law, Sherrington*.

**sidebending**: Movement in a coronal (frontal) plane about an anterior-posterior (x) axis. Also called lateral flexion, lateroflexion, or flexion right (or left).

**sidebent**: The position of any one or several vertebral bodies after sidebending has occurred. (Fig. 56) See also *sidebending*.

**skin drag**: Sense of resistance to light traction applied to the skin. Related to the degree of moisture and degree of sympathetic nervous system activity.

**soft tissue (ST)**: See *osteopathic manipulative treatment, soft tissue*.

**soft tissue technique**: See *osteopathic manipulative treatment, soft tissue technique*.

**somatic dysfunction**: Impaired or altered function of related components of the somatic (body framework) system: skeletal, arthrodiastal and myofascial structures, and their related vascular, lymphatic, and neural elements. Somatic dysfunction is treatable using osteopathic manipulative treatment. The positional and motion aspects of somatic dysfunction are best described using at least one of three parameters: 1). The position of a body part as determined by palpation and referenced to its adjacent defined structure, 2). The directions in which motion is freer, and 3). The directions in which motion is restricted. See also *T.A.R.T.* See also *S.T.A.R.*

**acute s. d.**, immediate or short-term impairment or altered function of related components of the somatic (body framework) system. Characterized in early stages by vasodilation, edema, tenderness, pain and tissue contraction. Diagnosed by history and palpatory assessment of tenderness, asymmetry of motion and relative position, restriction of motion and tissue texture change (T.A.R.T.). See also *T.A.R.T.*

**chronic s. d.**, impairment or altered function of related components of the somatic (body framework) system. It is characterized by tenderness, itching, fibrosis, paresthesias and tissue contraction. Identified by T.A.R.T. See also *T.A.R.T.*

**linkage**, dysfunctional segmental behavior where a single vertebra and an adjacent rib respond to the same regional motion tests with identical asymmetric behaviors (rather than opposing behaviors). This suggests visceral reflex inputs.

**primary s. d.**, 1. The somatic dysfunction that maintains a total pattern of dysfunction. See also *key lesion*. 2. The initial or first somatic dysfunction to appear temporally.

**secondary s. d.**, somatic dysfunction arising either from mechanical or neurophysiologic response subsequent to or as a consequence of other etiologies.

**type I s. d.**, 1. A group curve of thoracic and/or lumbar vertebrae in which the freedoms of motion are in neutral with sidebending and rotation in opposite directions with maximum rotation at the apex (rotation occurs toward the convexity of the curve) based upon the Principles of Fryette. (American usage). 2. Second degree

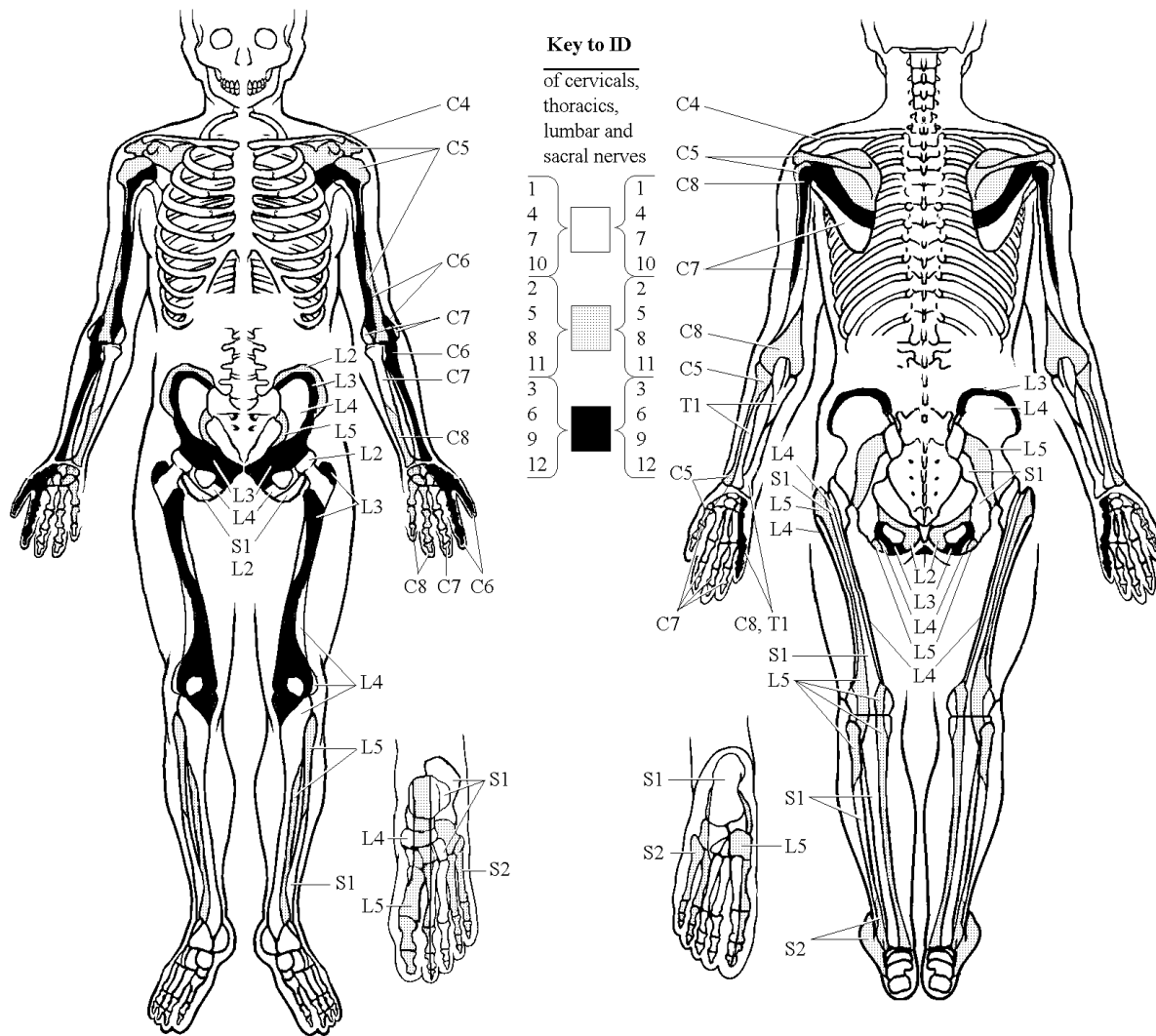


Figure 54. Anterior and posterior sclerotomal innervations. (Modified from Foundations for Osteopathic Medicine, Ward RC—Ed., William & Wilkins; 1997:644).

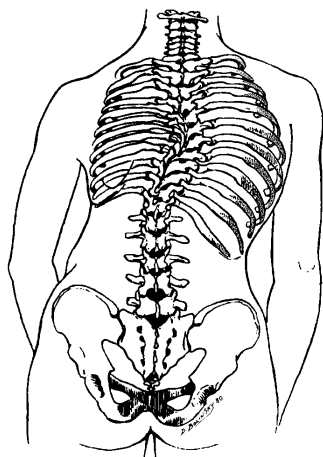


Figure 55. Scoliosis.

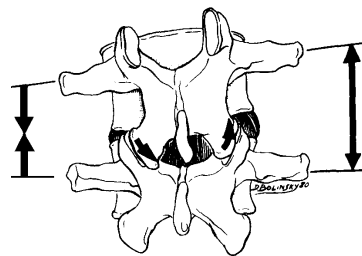


Figure 56. Sidebent.

dysfunction based upon the Laws of Lovett (French usage).

**type II s. d., 1.** Thoracic or lumbar somatic dysfunction of a single vertebral unit in which the vertebra is significantly flexed or extended with sidebending and rotation in the same direction (rotation occurs into the concavity of the curve) based upon the Principles of Fryette (American usage).  
**2.** First degree dysfunction based upon the Laws of Lovett (French usage).

**somatogenic:** That which is produced by activity, reaction and change originating in the musculoskeletal system.

**somatosomatic reflex:** See reflex, somatosomatic r.

**somatovisceral reflex:** See reflex, somatovisceral r.

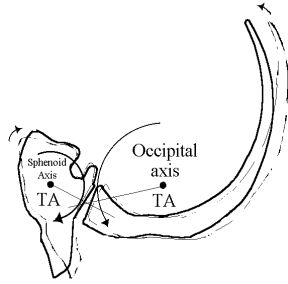


Figure 57. Extension (SBS).

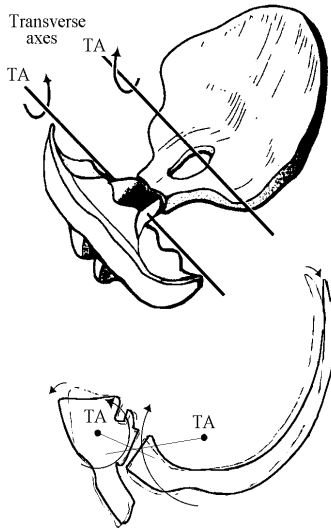


Figure 58. Flexion (SBS).

**spasm:** (compare with hypertonicity) a sudden, violent, involuntary contraction of a muscle or group of muscles, attended by pain and interference with function, producing involuntary movement and distortion (*Dorland's*).

**Spencer technique:** See *osteopathic manipulative treatment, Spencer technique*.

**sphenobasilar synchondrosis (symphysis), somatic dysfunctions of:** any of a group of somatic dysfunctions involving primarily the inter-relationship between the basilar portion of the sphenoid (basisphenoid) and the basilar portion of the occiput (basiocciput). The abbreviation, SBS, is often used in reporting the following somatic dysfunctions:

**SBS compression,** somatic dysfunction in which the basisphenoid and basiocciput are held forced together significantly limiting SBS motion.

**SBS extension,** sphenoid and occiput have rotated in opposite directions around parallel transverse axes; the

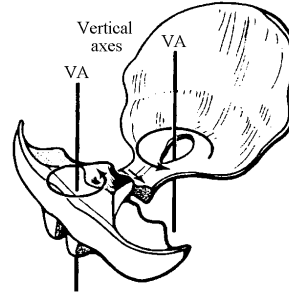


Figure 59. Right lateral strain (SBS).

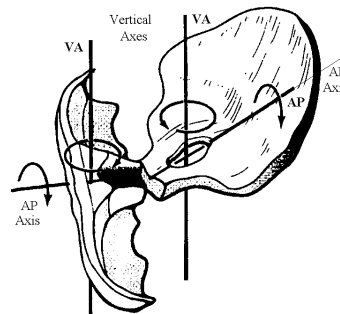


Figure 60. Left sidebending/rotation (SBS).

basiocciput and basisphenoid are both inferior in SBS extension with a decrease in the dorsal convexity between these two bones. (**Fig. 57**)

**SBS flexion,** sphenoid and occiput have rotated in opposite directions around parallel transverse axes; the basiocciput and basisphenoid are both superior in SBS extension with an increase in the dorsal convexity between these two bones. (**Fig. 58**)

**lateral strain,** sphenoid and occiput have rotated in the same direction around parallel vertical axes. Lateral strains of the SBS are named for the position of the basisphenoid, right or left. (**Fig. 59**)

**sidebending-rotation,** sphenoid and occiput have rotated in opposite directions around parallel vertical axes and rotate in the same direction around an A-P axis. SBS sidebending-rotations are named for the convexity, right or left. (**Fig. 60**)

**torsion,** sphenoid and occiput have rotated in opposite directions around an anterior-posterior (A-P) axis. SBS torsions are named for the high greater wing of the sphenoid, right or left. (**Fig. 61**)

**vertical strain,** sphenoid and occiput have rotated in the same direction

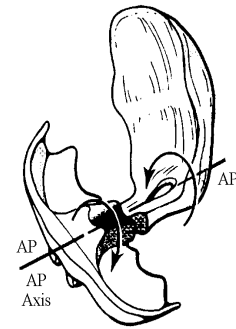


Figure 61. Right torsion (SBS).

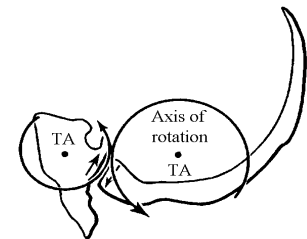


Figure 62. Superior vertical strain (SBS).

around parallel transverse axes.

Vertical strains of the SBS are named for the position of the basisphenoid, superior or inferior. (**Fig. 62**)

**spinal facilitation:** 1. The maintenance of a pool of neurons (e.g., premotor neurons, motor neurons or preganglionic sympathetic neurons in one or more segments of the spinal cord) in a state of partial or subthreshold excitation; in this state, less afferent stimulation is required to trigger the discharge of impulses. 2. A theory regarding the neurophysiological mechanisms underlying the neuronal activity associated with somatic dysfunction. 3. Facilitation may be due to sustained increase in afferent input, aberrant patterns of afferent input, or changes within the affected neurons themselves or their chemical environment. Once established, facilitation can be sustained by normal central nervous system (CNS) activity.

**splenic pump technique:** See *osteopathic manipulative treatment, splenic pump technique*.

**spondylo-:** Combining form denoting relationship to a vertebra, or to the spinal column (*Dorland's*).

**spondylitis:** Inflammation of vertebrae. (*Dorland's*).

**spondylolisthesis:** Anterior displacement of one vertebra relative to one immediately below (usually L-5 over the body of the sacrum or L-4 over L-5).

**spondylolysis:** Dissolution of a vertebra, aplasia of the vertebral arch, and separation at the pars interarticularis; platyspondylia, pre-spondylolisthesis.

**spondylosis:** 1. Ankylosis of adjacent vertebral bodies. 2. Degeneration of the intervertebral disk.

**spontaneous release by positioning:** See *osteopathic manipulative treatment, counterstrain*.

**sprain:** Stretching injuries of ligamentous tissue (compare with strain). First degree: microtrauma; second degree: partial tear; third degree: complete disruption.

**springing technique:** See *osteopathic manipulative treatment, springing technique*. See also *osteopathic manipulative treatment, articular treatment system*.

**sphinx test:** See *backward bending test*.

**spring test:** 1. A test used to differentiate between backward or forward sacral torsions/rotations. 2. A test used to differentiate bilateral sacral extension and bilateral sacral flexion. 3. A test used to differentiate unilateral sacral extension and unilateral sacral flexion.

**S.T.A.R.:** A mnemonic for four diagnostic criteria of somatic dysfunction: sensitivity changes, tissue texture abnormality, asymmetry and alteration of the quality and quantity of range of motion.

**static contraction:** See *contraction, isometric contraction*.

**Still, MD, DO:** Andrew Taylor. Founder of osteopathy; 1828-1917. First announced the tenets of osteopathy on June 22, 1874, established the American School of Osteopathy in 1892 at Kirksville, MO.

**still point:** A term used to identify and describe the temporary cessation of the rhythmic motion of the primary respiratory mechanism. It may occur during osteopathic manipulative treatment when a point of balanced membranous or ligamentous tension is achieved. 2. A term used by William G. Sutherland, DO.

**Still Technique:** See *osteopathic manipulative treatment, Still Technique*.

**strain:** 1. Stretching injuries of muscle tissue. 2. Distortion with deformation of tissue. See also *ligamentous strain*.

**Strachan model:** See *sacrum, somatic dysfunctions of, anterior sacrum*. See

*sacrum, somatic dysfunctions of, posterior sacrum*.

**Strain-Counterstrain®:** See *osteopathic manipulative treatment, counterstrain*.

**stretching:** Separation of the origin and insertion of a muscle and/or attachments of fascia and ligaments.

**stringiness:** A palpable tissue texture abnormality characterized by fine or stringlike myofascial structures.

**structural examination:** See *osteopathic structural examination*.

**subluxation:** 1. A partial or incomplete dislocation. 2. A term describing an abnormal anatomical position of a joint which exceeds the normal physiologic limit, but does not exceed the joint's anatomical limit.

**superior (upslipped) innominate:** See *innominate, somatic dysfunctions of, superior innominate shear*.

**superior pubic shear:** See *pubic bone, somatic dysfunctions of*. See also *symphyseal shear*. (Fig. 31)

**superior transverse axis:** See *sacral motion axis, superior transverse axis (respiratory) and (z) axis*.

**supination:** 1. Beginning in anatomical position, applied to the hand, the act of turning the palm forward (anteriorly) or upward, performed by lateral external rotation of the forearm. 2. Applied to the foot, it generally applies to movements (adduction and inversion) resulting in raising of the medial margin of the foot, hence of the longitudinal arch. A compound motion of plantar flexion, adduction and inversion. See also *pronation*.

**supine:** Lying with the face upward (*Dorland's*).

**symmetry:** The similar arrangement in form and relationships of parts around a common axis, or on each side of a plane of the body (*Dorland's*).

**Sutherland fulcrum:** A shifting suspension fulcrum of the reciprocal tension membrane located along the straight sinus at the junction of the falx cerebri and tentorium cerebelli. See also *reciprocal tension membrane*. See also *osteopathic manipulative treatment, Osteopathy in the Cranial Field (OCF)*.

**symphyseal shear:** The resultant of an action or force causing or tending to cause the two parts of the symphysis to slide relative to each other in a direction parallel to their plane of contact. It is usually found in an inferior/superior direction but is occasionally found to be in an anterior/posterior direction. (Fig. 28, Fig. 31)

## T

**tapotement:** Striking the belly of a muscle with the hypothenar edge of the open hand in rapid succession in an attempt to increase its tone and arterial perfusion.

**T.A.R.T.:** A mnemonic for four diagnostic criteria of somatic dysfunction: tissue texture abnormality, asymmetry, restriction of motion and tenderness, any one of which must be present for the diagnosis.

**technic:** See *technique*.

**technique:** Methods, procedures and details of a mechanical process or surgical operation. (*Dorland's*). See also *osteopathic manipulative treatment*.

**tenderness:** 1. Discomfort or pain elicited by the osteopathic practitioner through palpation. 2. A state of unusual sensitivity to touch or pressure (*Dorland's*).

**tender points:** 1. Small, hypersensitive points in the myofascial tissues of the body that do not have a pattern of pain radiation. These points are a manifestation of somatic dysfunction and are used as diagnostic criteria and for monitoring treatment. 2. A system of diagnosis and treatment originally described by Lawrence Jones, DO, FAAO. See also *osteopathic manipulative treatment, counterstrain*.

**terminal barrier:** See *barrier, physiologic b*.

**thoracic aperture (superior):** See *thoracic inlet*.

**thoracic outlet:** 1. The functional thoracic inlet consists of T1-4 vertebrae, ribs 1 and 2 plus their costicartilages, and the manubrium of the sternum. See *fascial patterns*. 2. The anatomical thoracic inlet consists of T1 vertebra, the first ribs and their costal cartilages, and the superior end of the manubrium.

**thoracic pump:** See *osteopathic manipulative treatment, thoracic pump*.

**thrust technique:** See *osteopathic manipulative treatment, thrust technique*. See also *osteopathic manipulative treatment, high velocity/low amplitude technique (HVLA)*.

**tissue texture abnormality (TTA):** A palpable change in tissues from skin to periarticular structures that represents any combination of the following signs: vasodilation, edema, flaccidity, hypertonicity, contracture, fibrosis, as well as the following symptoms: itching, pain, tenderness, paresthesias. Types of TTA's include: bogginess, thickening, stringiness, ropiness,



firmness (hardening), increased/decreased temperature and increased/decreased moisture.

**toggle technique:** See *osteopathic manipulative treatment, toggle technique*.

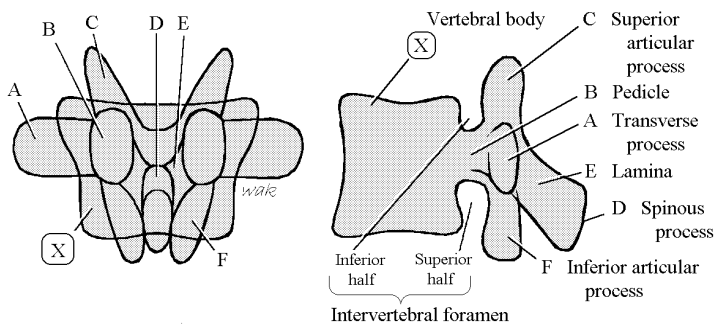
**tonus:** The slight continuous contraction of muscle, which in skeletal muscles, aids in the maintenance of posture and in the return of blood to the heart (*Dorland's*).

**torsion:** 1. A motion or state where one end of a part is twisted about a longitudinal axis while the opposite end is held fast or turned in the opposite direction. 2. An unphysiologic motion pattern about an anteroposterior axis of the sphenobasilar symphysis/synchondrosis. See also *sphenobasilar synchondrosis (symphysis), somatic dysfunctions of, torsion*.

**torsion, sacral:** See *sacral torsion*. See also *sacrum, somatic dysfunctions of, sacral torsions*.

**traction:** A linear force acting to draw structures apart.

**traction technique:** See *osteopathic manipulative treatment, traction technique*.



**Figure 63. The pedicle (B) is the key structure from which other vertebral parts can be identified.** (Ward RC, Ex. Ed., *Foundations for Osteopathic Medicine*, Second Edition, Lippincott Williams & Wilkins, Philadelphia, 2003:730.

**transitional region:** Areas of the axial skeleton where structure changes significantly lead to functional changes; transitional areas commonly include the following:

**occipitocervical region (OA),** typically the OA-AA-C2 region is described.

**cervicothoracic region (CT),** typically C7-T1.

**thoracolumbar region (TL),** typically T10-L1.

**lumbosacral region (LS),** typically L5-S1.

**transitional vertebrae:** A congenital anomaly of a vertebra in which it

develops characteristic(s) of the adjoining structure or region.

**lumbarization,** a transitional segment in which the first sacral segment becomes like an additional lumbar vertebra articulating with the second sacral segment.

**sacralization,** 1. Incomplete separation and differentiation of the fifth lumbar vertebra (L5) such that it takes on characteristics of a sacral vertebra. 2. When transverse processes of the fifth lumbar (L5) are atypically large, causing pseudoarthrosis with the sacrum and/or ilia(um), referred to as batwing deformity, if bilateral.

**translation:** Motion along an axis.

**translatory motion:** See *motion, translatory motion*.

**transverse axis of sacrum:** See *sacral, sacral movement axis, transverse (z) axis*. (Fig. 37)

**transverse process:** Projects laterally from the region of each pedicle. The pedicle connects the posterior elements to the vertebral body. (Fig. 63)

**transverse rib axis:** See (Fig. 35). See also *rib motion, pump handle rib motion*. (Fig. 34)

**treatment, osteopathic manipulative techniques:** See *osteopathic manipulative treatment*.

**Trendelenburg test:** The patient, with back to the examiner, is told to lift first one foot and then the other. The position and movements of the gluteal fold are watched. When standing on the affected limb the gluteal fold on the sound side falls instead of rising. Seen in poliomyelitis, un-united fracture of the femoral neck, coxa vara and congenital dislocations.

**trigger point (myofascial trigger point):**

1. A small hypersensitive site that, when stimulated, consistently produces a reflex mechanism that gives rise to referred pain and/or other manifestations in a consistent reference zone that is consistent from person to person. 2. These points were most extensively and systematically documented by Janet Travell, MD, and David Simons, MD.

**trophic:** Pertaining to nutrition, especially in the cellular environment (e.g., trophic function — a nutritional function).

**trophicity:** 1. A nutritional function or relation. 2. The natural tendency to replenish the body stores that have been depleted.

**trophotropic:** Concerned with or pertaining to the natural tendency for maintenance and/or restoration of nutritional stores.

**-tropic:** A word termination denoting turning toward, changing or tendency to change.

**tropism, facet:** Unequal size and/or facing of the zygapophyseal joints of a vertebra. See also *facet asymmetry*.

**type I somatic dysfunction:** See *somatic dysfunction, type I s.d*. See also *physiologic motion of the spine*.

**type II somatic dysfunction:** See *somatic dysfunction, type II s.d*. See also *physiologic motion of the spine*

## U

**uncommon compensatory pattern:** See *fascial patterns, uncommon compensatory pattern*.

**uncompensated fascial pattern:** See *fascial patterns, uncompensated fascial pattern*.

## V

**v-spread:** See *osteopathic manipulative treatment, v-spread*.

**velocity:** The instantaneous rate of motion in a given direction.

**Traube-Herring-Mayer wave:** An oscillation that has been measured in association with blood pressure, heart rate, cardiac contractility, pulmonary blood flow, cerebral blood flow and movement of the cerebrospinal fluid, and peripheral blood flow including venous volume and thermal regulation. This whole-body phenomenon, which exhibits a rate typically slightly less than and independent of respiration, bears a striking resemblance to the primary respiratory mechanism.

**Travell trigger point:** See *trigger point*.

**treatment, active:** (archaic). See *osteopathic manipulative treatment, active method*.

**ventral technique:** See *osteopathic manipulative treatment, visceral manipulation*.

**vertebral unit:** Two adjacent vertebrae with their associated intervertebral disk, arthroial, ligamentous, muscular, vascular, lymphatic and neural elements. (Fig. 64)

**visceral dysfunction:** Impaired or altered mobility or motility of the visceral system and related fascial, neurological, vascular, skeletal and lymphatic elements.

**visceral manipulation:** See *osteopathic manipulative treatment, visceral manipulation*.

**viscerosomatic reflex:** See *reflex, viscerosomatic r.*

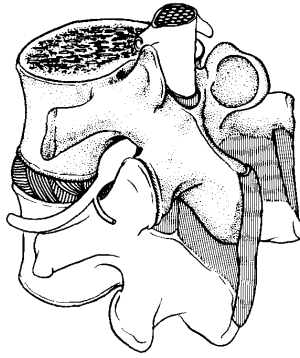


Figure 64. Vertebral unit.

**viscerovisceral reflex:** See *reflex, viscerovisceral r.*

**viscosity:** 1. A measurement of the rate of deformation of any material under load. 2. The capability possessed by a solid of yielding continually under stress. See also *elasticity*. See also *plasticity*.

## W

**weight-bearing line of L3:** See *gravitational line*. (Fig. 16) **vertical axis:** See *sacral motion axis, vertical (y) axis (longitudinal)*.

---

File: D:/Glossary/Glossary of 08-15-2006